Case Report
Journal of Karnataka Orthopaedic Association 2018 Jan-Apr;6(1):46-48

Late Transverse Patellar fracture following patellar tendon reconstruction using semitendinosus graft via single transverse tunnel

Varshini A[1], Sandesh Madi[1], Vivek Pandey[1], Mohd Suhaib Mudabbir[1]

Abstract

Chronic neglected rupture of patellar tendon is a rare but a disabling injury which requires patellar tendon reconstruction to restore the optimal function of the knee. Though many techniques are described in literature to reconstruct the patellar tendon, use of ipsilateral semitendinosus tendon through transverse patellar tunnel is one of the method used to reconstruct the patellar tendon. However, the transverse tunnel acts as a stress riser and could lead to a fracture. We report a rare case of late transverse fracture patella following the patellar tendon reconstruction in a neglected injury using ipsilateral semitendinosus and its management.

Keywords: transverse patella fracture, reconstruction of patella tendon rupture, complication

Introduction

The management of chronic patella tendon rupture poses a significant challenge as restoration of knee function is not an easy goal. Many techniques are described in literature to reconstruct the patellar tendon rupture using various auto- or allograft [1]. One of the common technique involves use of Semitendinosus tendon which is tunnelled across the patella through transverse tunnel to reconstruct the patellar tendon [2]. However, the tunnel(s) drilled in the patella could act like a stress riser which can lead to transverse patellar fractures [3-5]. Most reported cases of stress fracture are after medial patellofemoral ligament reconstruction or Quadriceps tendon repair but not after patellar tendon reconstruction. For the first time perhaps, we are reporting a transverse fracture in patella after a patellar tendon reconstruction for a neglected patella tendon rupture.

[1]Dept. of Orthopaedics, KMC, Manipal, Manipal Academy of Higher Education.

Address of correspondence :
Dr. Sandesh S Madi
Dept. of Orthopaedics, KMC, Manipal, Manipal Academy of Higher Education
Email: sandesh.madi@gmail.com

Case report

A twenty nine-year-old female, presented to our Knee clinic with chief complaint of pain in right knee and difficulty in climbing stairs following a direct open trauma to the knee three months back. She had pain, swelling and an open wound over the knee, and was unable to walk. She visited a general surgical clinic where the laceration was sutured under local anaesthesia and medications were prescribed. However, she continued to walk with limp and pain for next three months. Clinical examination revealed high riding patella with a healed transverse scar in front of the knee. Further, a gap was felt inferior to patella over the patellar tendon area. There was extensor lag of 40^0. The knee range of movement was 0-140^0. Rest of the examination was normal. A clinical diagnosis of neglected patellar tendon rupture was made. Plain radiographs of knee were taken in Anteroposterior, lateral and axial views (Figure 1A). Magnetic resonance imaging (MRI) of the knee confirmed tear of the patellar tendon with proximal migration of patella with no other intraarticular injuries [figure 1B]. Patellar tendon reconstruction was planned using ipsilateral semitendinosus (ST) autograft. Under spinal anaesthesia and tourniquet control, a ten centimetre long incision was made from tibial tuberosity towards the patella. Subcutaneous tissue was incised. The ST tendon was harvested from medial tibia in standard fashion keeping the distal end attached to the tibia. The muscle fibres were separated and proximal end of ST tendon was prepared using No.2 Ethibond suture (Ethicon, Johnson and Johnson, USA). A transverse tunnel was drilled in middle third of patella from medial to lateral using 4.5mm drill bit. Further, another oblique tunnel of six mm diameter was made just under the tibial tuberosity. The ST graft was now passed via patellar tunnel from medial to lateral and then pulled into the sub-tibial tuberosity tunnel. The ST graft was fixed with six mm bio absorbable interference screw (Mitek, Depuy, Johnson and Johnson, USA). Patient was kept non-weight bearing in an extension brace for two weeks. The knee was gradually mobilised along with quadriceps strengthening exercises. At the end of three months review, patient regained 0-130^0, without extensor lag and full weight bearing was allowed. At 6 months review, patient had grade 5 extensor power with full movement. After three years post-

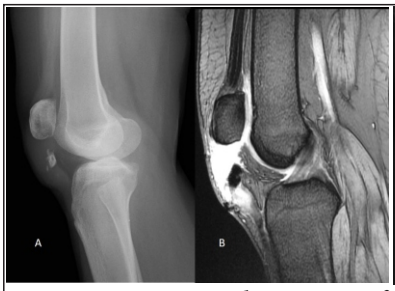

Figure 1: 1A, proximal migration of patella after patella tendon rupture. 1B; MRI showing ruptured patella tendon.

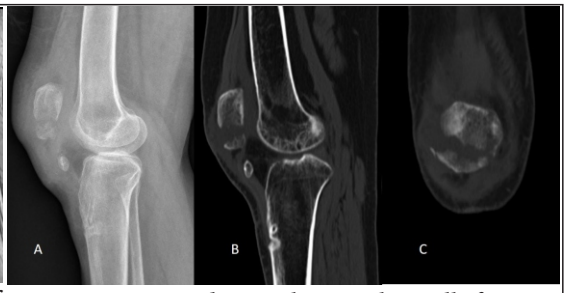

Figure 2: 2A, xray showing lower pole patella fracture. 2B,C; CT scan showing transverse fracture patella through the tunnel.

operatively, patient sustained a trivial fall, and injured her right knee. Radiological examination revealed transverse fracture of right patella just through the inferior part of bony tunnel in the patella [Figure 2A]. CT scan confirmed the findings [Figure 2B, C]. A week later, the transverse fracture of patella was fixed with a single 4.5 mm cannulated cancellous screw [Synthes, US] augmented with multiple no.2 fibre wire (Arthrex, Naples, FL, USA) via transosseous tunnels drilled in superior and inferior fragments of patella using 2 mm K wire [Figure 3A-C]. The ST graft was found to be intact. Immediate post-operatively, the knee was immobilised in extension brace. At 10th post-operative day, knee was mobilized with a hinged self-adjustable range of movement brace, allowing 0-45^0 degrees initially to 0-90^0 degrees in 5 days and patient was discharged. At 3 month follow-up, patient had 0-90^0 degrees of flexion with quadriceps with grade 4 power. At one year post surgery, patient had no complaints with range of motion 0-90^0 degrees with quadriceps grade 5, without extensor lag [figure 4]. However, she was not able to perform squatting. Her final objective IKDC grade was C whereas Lysholm score was 86.

Discussion

Discussion

The incidence of patella tendon ruptures is reported to be 0.68/100,000 and generally seen in older individuals with a mean age of 49 years (male) and 69 years (female) [6]. Tendon ruptures presenting six weeks after the injury are generally termed as chronic/neglected and the exact incidence of these neglected patella tendon ruptures is unknown. Patella tendon rupture can be seen both in low velocity (degenerative tendon) as well as high velocity injuries (open injuries). Iatrogenic ruptures are also reported during or following common knee surgeries such as total knee replacement and ACL reconstruction using BTB graft. Clinical presentation is characterised by triad of a gap in the native patella region, a high riding patella and an extensor lag. In chronic neglected cases, reconstruction of the tendon has to be contemplated. There is no single gold standard technique and results are quite variable. Available choices include Allografts (patella tendon, Achilles tendon), Autografts (ipsilateral hamstrings, Fascia lata, contralateral patella tendon) or Synthetics (Dacron) [7]. Extensive scarring and quadriceps contracture with atrophy makes patella mobilisation difficult and challenging to restore a normal patella height. Possible complications following reconstruction for neglected patella tendon ruptures include re-rupture of the grafts, breakage of augmentation (cerclage wires, Fibrewires, PDS), infections, residual extensor lag, persistent anterior knee pain, hypoesthesia over anterior aspect of the knee and DVT (from prolonged immobilisation). Transverse patellar fracture is a likely complication after any procedure where in a transverse tunnel is made [3, 8-10]. Around 80% of fractures occur in between middle and lower third of patella [11]. Stress fractures usually propagate along the lines of weakened architecture. Singh et al were the first to report a case of stress fracture of patella following patella tendon repair. The patella tendon avulsion was repaired by passing non absorbable suture through three 2.5mm transosseous tunnels in the patella and further protected by stainless steel wire loop across the patella. A subsequent twisting injury resulted in comminuted fracture of the patella which warranted fracture fixation by tension band wiring and encirclage [4]. Similar cases have been reported for acute quadriceps repair and more commonly for patella instability surgeries. However, according to authors' knowledge, there are no reports in the literature about a late patella fracture after the patellar tendon reconstruction using a semitendinosus tendon. There are many factors in this scenario which can increase the stress on patella. The drilling itself leads to a structurally weakened bone especially if anterior cortex of patella is breached [12]. The patellar tunnel traversing the entire width of patella is known to have increased risk of the fracture [8]. However, in a recent cadaveric study, it was observed that two transosseous transverse tunnels with or without breaching the anterior cortex of the patella did not decrease the load to failure as

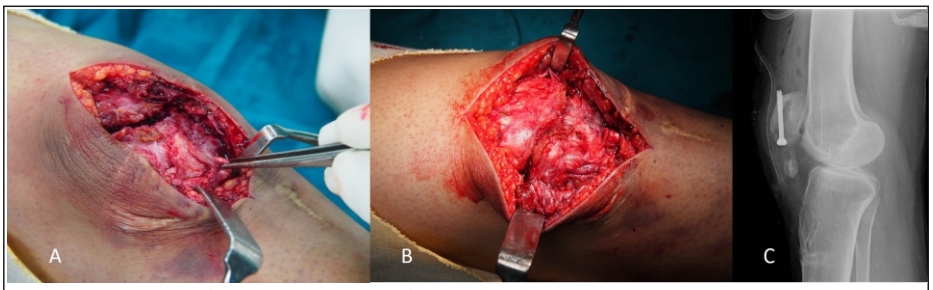

Figure 3: 3A shows fracture patella with forceps holding the intact semitendinosus tendon. 3B shows reconstructed mechanism.3C shows fracture reduction with 4.5mm cannulated cancellous screw.

Figure 4: No extensor lag and flexion of 90 degrees.

compared to native patella [13]. Secondly, a wider tunnel comparatively has more fractures reported [10]. The dual tunnel increases more stress on patella compared to single tunnel. It is found out that if dual tunnel bridge is less it destabilises the patella. When both medial retinacula dissection and lateral retinacula release is done in a surgery they act as stress risers which propagate a tear [14]. Around 56% of vascular compromise was shown when lateral release was done with total knee arthroplasty [15]. A relatively avascular patella is more prone for fractures. Prolonged immobilisation during rehabilitation would lead to a state of disuse osteopenia and weaken the bone further. When non-absorbable suture materials are used in transosseous acute patella tendon repairs, it was postulated that the drill holes may persists for a longer time resulting in a potential area of weakness [4]. Further, it was suggested that these sutures can possibly produce cystic changes within the tunnel as a result of either a foreign body reaction or from repetitive micromotion of the suture within the tunnel [3]. While the hamstring tendon grafts are shown to have many advantages they are shown to have increased laxity over time and also are responsible for tunnel enlargement. The aggressive rehabilitation protocol can increase the graft tunnel motion and enlarge it [16]. An enlarged tunnel in a porotic patella could lead to fracture. Further, there is evidence that cytokines cause inflammation and lead to the enlargement of tunnel [17]. This can contribute in causing a fracture in patella. A trivial fall could lead to fracture of patella which is already weakened by enlarged tunnel and a porotic patella which is relatively avascular.

Learning points

- This is perhaps a first report of late transverse Patellar fracture following patellar tendon reconstruction in a neglected injury using semitendinosus graft via single transverse tunnel
- Neglected patella tendon ruptures are rare injuries and difficult to manage
- Transverse tunnel through the patella for the graft passage is a stress riser and a risk for potential patella fracture
- Adequate caution during drilling the tunnels, preservation of vascularity of patella during surgical dissection, protection of the reconstruction and early rehabilitation may avoid this potential complication.

References

1. Gilmore JH, Clayton-Smith ZJ, Aguilar M, Pneumaticos SG, Giannoudis PV. Reconstruction techniques and clinical results of patellar tendon ruptures: evidence today. The Knee. 2015 Jun 30;22(3):148-55.
2. Abdou YE. Reconstruction of a chronic patellar tendon rupture with semitendinosus autograft. Arch Orthop Trauma Surg. 2014 Dec 1;134(12):1717-21.
3. Gregory JM, Sherman SL, Mather R, Bach Jr BR. Patellar stress fracture after transosseous extensor mechanism repair: report of 3 cases. Am J Sports Med. 2012 Jul;40(7):1668-72.
4. Singh BI, Sinha S, Singh S, Shrivastava R, Mandalia VI. Stress fracture patella following patella tendon repair. Injury Extra. 2004 Feb 29;35(2):13-6.
5. Schiphouwer L, Rood A, Tigchelaar S, Koeter S Complications of medial patellofemoral ligament reconstruction using two transverse patellar tunnels. Knee Surg Sports Traumatol Arthrosc.2017; 25:245-250.
6. Serino J, Mohamadi A, Orman S, McCormick B, Hanna P, Weaver MJ, et al. Comparison of adverse events and postoperative mobilization following knee extensor mechanism rupture repair: A systematic review and network meta-analysis. Injury. 2017 Dec 1;48(12):2793-9.
7. Pengas IP, Assiotis A, Khan W, Spalding T. Adult native knee extensor mechanism ruptures. Injury. 2016 Oct 1;47(10):2065-70.
8. Takacs IM, Somford MP. Patellar Fracture after MPFL Reconstruction, a Case Report. MOJ Orthop Rheumatol 2016; 6(4): 00228
9. Mohammed R, Hunt N, Gibbon AJ. Patellar complications in single versus double tunnel medial patellofemoral ligament reconstruction. J Orthop Surg (Hong Kong) 2017 Feb 22; 25 (1):2309499017691007.
10. Shah JN, Howard JS, Flanigan DC, Brophy RH, Carey JL, Lattermann C A systematic review of complications and failures associated with medial patellofemoral ligament reconstruction for recurrent patellar dislocation. Am J Sports Med 2012; 40:1916-1923.
11. Nummi J Operative treatment of patellar fractures. Acta Orthop Scand 1971; 42:437-438
12. Ellera Gomes JL Medial patellofemoral ligament reconstruction for recurrent dislocation of the patella: a preliminary report. Arthroscopy 1992; 8:335-340
13. Lukosius E, Bonazza N, Lewis G, Roush E, Black KP, Dhawan A. Effect of Patellar Tunnel Placement on Fracture Risk after MPFL Reconstruction-A Cadaveric Study. Orthopaedic journal of sports medicine. 2017 Jul 21;5(7_suppl6):2325967117S00216.
14. Brennan SA, Walls R, Jackson M, Moran R Superior pole sleeve fracture following patellar stabilisation. Knee 2009; 16:235-237.
15. Scuderi G, Scharf SC, Meltzer LP, Scott WN The relationship of lateral releases to patella viability in total knee arthroplasty. J Arthroplasty 1987; 2:209-214
16. Rodeo SA, Arnoczky SP, Torzilli PA, Hidaka C, Warren RF Tendon-healing in a bone tunnel. A biomechanical and histological study in the dog. J Bone Joint Surg Am 1993; 75:1795-1803
17. Zysk SP, Fraunberger P, Veihelmann A, Dorger M, Kalteis T, Maier M, Pellengahr C, Refior HJ Tunnel enlargement and changes in synovial fluid cytokine profile following anterior cruciate ligament reconstruction with patellar tendon and hamstring tendon autografts. Knee Surg Sports Traumatol Arthrosc 2004; 12:98-103.

Conflict of Interest: NIL
Source of Support: NIL

How to Cite this Article

Varshini A, Madi S, Pandey V, Mudabbir MS. Late Transverse Patellar fracture following patellar tendon reconstruction using semitendinosus graft via single transverse tunnel. J Kar Orth Assoc. Jan-April 2018; 6(1):46-48