Original Article
Journal of Karnataka Orthopaedic Association 2018 May-Aug;6(2):7-11

Treatment of distal humerus extra-articular fractures using a single 3.5mm precontoured locking compression plate

Darshan Kumar A. Jain[1], Rahul P[1], Aubrey Conrad[1], Franco[1]

Abstract

Background: Extra-articular distal humerus fractures are relatively rare,and optimal surgical fixation is a quandary for orthopedic surgeons. The introduction of the extra-articular distal humerus locking plates has provided a viable option,and in our study, we have retrospectively analyzed 17 patients with extra-articular distal radius fracture surgically treated using the 3.5mm extra-articular distal humerus locking plate through the paratricipital approach.

Materials and Methods: A total of 17 patients with closed extra-articular fractures of the distal humerus presenting within 3weeks of injury were operated between June 2015 and July 2017 using the 3.5mm distal humerus extra-articular plate through the paratricipital approach. All patients were followed up for a minimum of 10months,and radiological and functional outcome were accessed. The Mayo Elbow performance score (MEPS)and the disabilities of arm, shoulder,and hand (DASH)questionnaire were employed.

Results: The mean age of patients was 40.6 years (range 18–60 years) with 9females and 8males. All fractures united with a mean time to union of 16.94 weeks (range 14–20 weeks). The mean follow-up period was 12.5 months(range 10–15 months). Preoperatively two patients had radial nerve palsy andpostoperatively one patient developed radial nerve palsy, all had neuropraxia and recovered completely. 15 patients had excellent results,and two patients had good results using MEPS,and the mean DASH score was 14.6 ± 5.4.

Conclusion: Extra-articular distal humerus fractures can be treated successfully by a single precontoured extra-articular distal humerus locking compression plate with minimal soft tissue injury and good functional outcome.

Keywords: Distal humerus fracture, extra-articular, locking plate.

Introduction

Extra-articular distal humerus fractures are relatively uncommon injuries and occur at the junction between the humeral shaft and the intercondylar region [1].The aim of surgical management is to restore alignment and achieve stable fixation to allow early range of movement and prevent elbow stiffness, which is a common problem with distal humerus fractures [2]. The current role of conservative management - functional bracing is limited to elderly patients unfit for surgery. Surgical options include, 4.5 mm dynamic compression plate and 3.5 mm distal humerus locking compression plates (LCP) in orthogonal or parallel patterns. The addition of the distal humerus extra-articular plate has added the advantage of using a single posterolateral compression plate for fixation of extra-articular fractures with a decreased need for extensive soft tissue dissection and periosteal stripping with decreased surgical time and potentially faster rehabilitation due to minimal soft tissue injury. The extra-articular distal humerus plate is an anatomically precontoured plate with a tapered end design to minimize soft tissue irritation and increased hole density distally so as to provide 5 screws in the distal fragment. The plate is placed centrally over the shaft with the distal portion over the lateral column. Studies have shown that the posterolateral plate is biomechanically superior to the 3.5 mm LCP in case of distal humeral diaphyseal osteotomies [3]. We studied the clinical and functional outcomes using a single extra-articular distal humerus plate in the management of extra-articular fractures of the distal humerus.

[1]Department of Orthopaedics, Ramaiah Medical College & Hospital, Bangalore.

Address of correspondence
Dr. Darshan Kumar A. Jain,
Department of Orthopaedics, Ramaiah Medical College & Hospital, Bangalore.
Email: jaindarshan81@gmail.com

Materials and Methods

Ethical review board permission was obtained,and consent was obtained from each patient. From June 2014 to July 2016, 17 extra-articular distal humerus diaphyseal fractures in adults were surgically treated using the 3.5mm distal humerus extra-articular plate through the paratricipital approach.

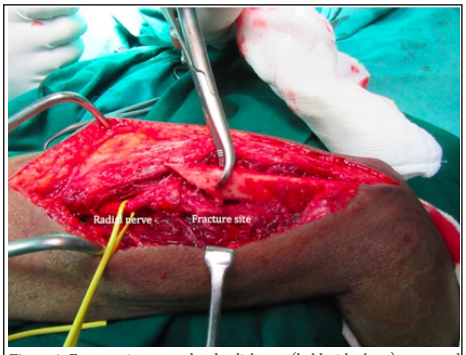

Figure 1: Fracture site exposed and radial nerve(held with a loop) entrapped at the fracture site.

Patients with displaced unstable distal humerus diaphyseal fractures and fracture with extension to metaphysis were included. Exclusion criteria were open fractures, fractures that extended into the joint and pathological fractures. There were eight men and nine women with a mean age of 40.6 years, range (18–60) with nine being left sided and eight right sided. Mechanism of injury was road traffic accident in 11 patients,and four had a history of fall and one each sustained fracture after a history of assault and arm wrestling. The fractures were classified according to AO/OTA. All patients were followed up for a minimum of 10months. Radiographs were obtained of the arm including shoulder and elbow, and neurological status was documented. All surgeries were performed by a single surgeon under general anesthesia/regional anesthesia with the patient positioned laterally with the affected arm up and supported over a bolster facilitating intraoperative image intensifier use without the use of a tourniquet. A posterior triceps-sparing approach (paratricipital) was used with a longitudinal skin incision made over the posterior aspect of the arm and extending distally between the lateral epicondyle and the tip of the olecranon distal to the elbow joint. The triceps fascia was split,and triceps then mobilized ulnarwards from the lateral intermuscular septum, distally the anconeus muscle was detached from the radial column when required. The triceps muscle is then retracted medially exposing the posterior humeral shaft and fracture site (Fig. 1). In cases where the fracture extended proximal to the midshaft, a window was made in the triceps muscle to aid screw fixation. Fracture was reduced under the vision and temporarily held with k wires or bone holding clamps and depending on the fracture configuration lag screws were applied before plate application. A 3.5mm side specific precontoured LCP distal humerus plate was placed and held with bone holding forceps. The plate has a 3.5mm combination hole system in the humeral shaft,and distally curves over the lateral supracondylar ridge with 5 screw holes angled medially to attain purchase in the trochlea and capitellum (Fig. 2). Final position was checked under image intensifier and closure done in layers over a drain. Drainwas kept for an average of 2days. This fracture is almost 10 cm proximal to olecranon tip, nerve is about 14cm from olecranon tip. How can you explain it as a distal metaphyseal fracture?

Postoperatively a well-padded dressing, arm pouch was given and X-ray is done

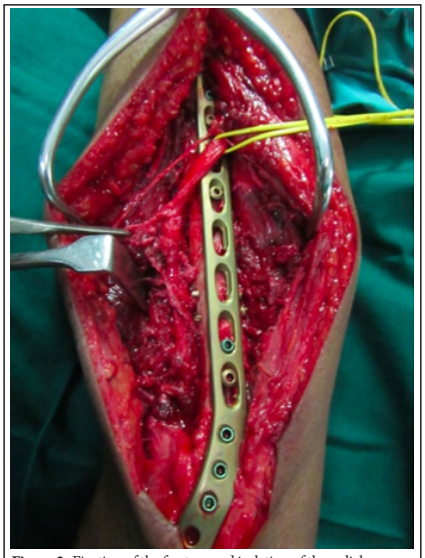

Figure 2: Fixation of the fracture and isolation of the radial nerve. This fracture is almost 10 cm proximal to olecranon tip.

(Fig. 3). Gentle shoulder and elbow mobilization were started from the 1stpost-operative day as tolerated by the patient and patient advised to continue the arm pouch until4–6weeks. Patients were followed clinically and radiologically in OPD for a minimum of 10months. Union was defined by the presence of bridging calluses in three of the four cortices on the anteroposterior and lateral radiographic views of the humerus (Fig. 4). Functional outcome was accessed using Mayo Elbow Performance Score (MEPS) and the disabilities of arm, shoulder, and hand (DASH) questionnaire at final follow-up. The MEPS consists of four parts-pain, motion, stability, and function and grades function of the elbow into excellent (≥90 points), good (75–89 points), fair (60–74 points), or poor (<60 points). The DASH questionnaire is a self-administered region-specific outcome instrument developed as a measure of self-rated upper-extremity disability and symptoms. The DASH consists mainly of a 30-item disability/symptom scale, scored 0 (no disability) to 100 and includes 30 items.

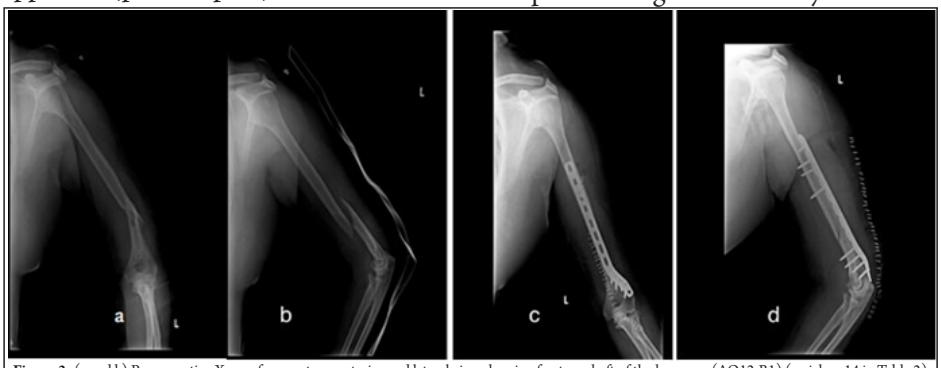

Figure 3: (a and b) Pre-operative X-ray of arm anteroposterior and lateral view showing fracture shaft of the humerus (AO12-B1) (serial no.14 in Table 2) (c andd) immediate post-operativeX-rays.

Results

In our retrospective study, 17 patients with distal humerus extra-articular fractures were operated using the extra-

Figure 4: X-rays are showing union at 17 weeks.

articular distal humerus plate system. The mean operation time was 111 min(± 13 min), meanintraoperative blood loss was 207mL,and the mean follow-up period was 12.5 ± 2.7 months (10–15 months). The most common fracture pattern was wedge type AO-12 B2. All fractures healed with a mean time to fracture union of 6.94 ± 2.96 weeks (14–20 weeks). 1 patient developed post-operative radial nerve palsy but later recovered after 12 weeks. No patients developed nonunion or had loss of reduction with no delayed wound healing or infection. The mean range of elbow flexion was 140 ± 6.5°with a functional arc of more than 130 degrees in all patients. Three patients had >10° of fixed flexion deformity (FFD). At final follow-up, the MEPS ranged between 85 and 100 and 88.2%(n=15) had excellent results and 11.7% (n=2) having a good score. The mean DASH score in our series was 14.62 ± 5.46.

Discussion

Extra-articular distal humerus fractures, as an entity requires special consideration due to its peculiar anatomy wherein surgical intervention for these lower metaphyseal fractures of the humerus aim to achieve stable reconstruction and proper alignment so as to facilitate an early range of movements. The role of conservative management in the form of functional bracing has seen a declining trend due to the increased high energy road traffic accidents, open fractures, and concomitant injuries elsewhere in the body.[2, 4] Open reduction and internal fixation are becoming an increasingly accepted modality. Conventionally these fractures are fixed with 4.5mm plates. The small size of the distal fragment and close proximity to the elbow joint(then hot to nail? Your photos show more proximal fractures)does not allow stable fixation with the standard plates. To overcome this problem, various modifications of plate osteosynthesis were used. Levy et al.[6]used a modified lateral tibial head plate buttress plate, Spitzer et al.[7] had demonstrated encouraging results with a hybrid metaphyseal LCP comprising of 4.5mm locking holes proximally and 3.5 mm locking holes distally whereas Saragagliaet al.[8]had introduced a "Lambda" plate which was an inverted Y-shaped plate with a stem and two sectile arms that can be easily remodeled according to the distal humerus contour, however none of them provide a reliable alternative.Dual plating has also been used for these fractures and offers a better biomechanical strength but requires a greater soft tissue dissection and exposure and can lead to potentially higher infection rate and elbow stiffness as reported by some series.Yang et al.[9,10,11] suggested that the extensive soft tissue dissection required for dual plating resulted in longer operation time and a higher rate of tenderness with an increased risk for iatrogenic radial nerve palsy as reported by other series. The extra-articular distal humerus plate is based on the concept of single column plating similar to the use of locking plates in the distal femur and proximal tibia fractures and can be used both as a fixed angled bridge plate and as a neutralization plate with lags screws. This implant allows for greater hold in the distal fragment due to the increased screw hole density,and the locking construct increases the stability. Meloyet al.[12]in his comparative study concluded that single column plating with precontoured posterolateral locking plate resulted in comparable union rates and alignment to dual column plating for extra-articular distal humerus fractures but with a significantly better range of movements

Table 1: Data after initial trauma

Pat No	Sex	Age, years	Mechanism of injury	Involved side	Fracture type	Associated injuries
1	F	60	Fall	Left	12-B2	None
2	F	28	RTA	Left	12-B2	None
3	F	57	RTA	Left	12-A1	None
4	F	42	Fall	Right	12-A1	None
5	M	60	Fall	Left	12-B1	None
6	F	24	RTA	Right	12-C2	Fracture shaft femur and tibia, ipsilateral ulna shaft
7	M	36	RTA	Left	12-B3	Right forearm both bones shaft fracture
8	M	37	RTA	Right	12-B2	None
9	F	29	RTA	Left	12-B1	None
10	F	35	RTA	Left	12-B1	None
11	M	41	RTA	Left	12-C2	None
12	F	51	Fall	Right	12-B3	None
13	M	18	Arm wrestling	Right	12-B1	None
14	M	42	RTA	Left	12-B1	None
15	M	37	Assault	Right	12-C2	None
16	F	51	RTA	Right	12-B2	None
17	M	43	RTA	Right	12-A2	None

Table 2: Results of patients with distal humerus extra-articular fracture

Patient no	Operation time,mins	Volume of blood loss, ml	Duration of follow up, months	Time to union,weeks	Elbow range of flexion,degrees	MPES	DASH score
1	120	200	12	17	0-130	100	9.2
2	100	150	10	15	0-145	100	4.2
3	100	100	12	15	0-140	100	5.8
4	140	300	16	20	0-135	95	14.2
5	130	300	19	22	0-135	95	21.7
6	130	200	10	16	0-150	90	19.2
7	100	150	18	19	0-145	100	14.2
8	120	200	10	12	15-135	85	23.3
9	110	200	12	20	0-140	95	12.5
10	120	250	12	15	0-150	100	17.5
11	100	200	12	17	0-145	85	20.8
12	110	200	10	15	10-130	100	15
13	120	200	10	12	10-135	95	11.7
14	90	200	14	17	0-140	100	19.2
15	110	250	11	22	0-145	100	16.7
16	100	200	13	18	0-145	100	14.2
17	100	200	12	16	0-135	100	9.2

with lesser complications. In our study, we used the paratricipital approach,and only the lateral column was exposed thereby decreasing the soft tissue dissection keeping the extensor mechanism intact and also allowing for exploration of the radial nerve. The medial intermuscular septum was left intact and ulnar nerve not dissected. In patients who had fractures with extension proximal to the middle third shaft, a small window was made in the triceps for screw fixation proximally. Postoperatively patients were given an arm pouch and physiotherapy initiated from the 1stpost-operative day,and we observed that most patients had a goodrange of movements as early as 6weeks. The mean age group of our patients was 40.6yearswith8males and 9females. All fractures united with a mean time to unionbeing 16.94 weeks which were similar to the recent studies, Capo et al.[13]- 7.3 months, Fawi et al. [14]- 15.7 weeks and 22.4 weeks as reported by Jain et al.[15]. The mean flexion was 140° with an arc of elbow movement of > than 130° in all patients. Two patients had 10°FFD,and one had 15° FFD, the possible reason being plate was placed higher,and the contour did not match that of the distal end humerus. In two patients we had to bend the plate to match the contour, as the plate was not seating well. Two patients had radial nerve palsy post-traumafor which neurolysis was doneand later patients recovered function by 10weeks. One patient sustained a spiral oblique distal humerus extra-articular fracture while arm wrestling. We had no infections or delayed wound healing. One patient developed radial nerve palsy postoperatively, however patient recovered function by 8weeks. All patients had good to the excellent return of elbow function as accessed by MEPS and DASH score and our results are consistent with other recent studies [13,14,15]. The limitations of our study were the small sample size and retrospective study with a lack of a comparison group.

Conclusion

The extra-articular distal humerus plate is a useful treatment option in the management of extra-articular distal humerus fractures as it provides a stable fixation and lesser exposure required leading to faster recovery period and good functional outcome.

References

1. Webb LX. Fractures of the distal humerus. In: Bucholz RW, Heckwan JD, editors. Rockwood and Green's Fractures in Adults. Philadelphia: Lippincott Williams and Williams; 2001. p. 953-72.
2. Jawa A, McCarty P, Doornberg J, Harris M, Ring D. Extra-articular distal-third diaphy- seal fractures of the humerus. A comparison of functional bracing and plate fixation. J Bone Joint Surg Am 2006;88:2343-7.
3. Scolaro JA, Hsu JE, Svach DJ, Mehta S. Plate selection for fixation of extra-articular distal humerus fractures: A biomechanical comparison of three different implants. Injury 2014;45:2040-4.
4. Fjalestad T, Strømsøe K, Salvesen P, Rostad B. Functional results of braced humeral diaphyseal fractures: Why do 38% lose external rotation of the shoulder? Arch Orthop Trauma Surg 2000;120:281-5.
5. Zimmerman MC, Waite AM, Deehan M, Tovey J, Oppenheim W. A biomechanical analysis of four humeral fracture fixation systems. J Orthop Trauma 1994;8:233-9.
6. Levy JC, Kalandiak SP, Hutson JJ, Zych G. An alternative method of osteosynthesis for distal humeral shaft fractures. J Orthop Trauma 2005;19:43-7.
7. Spitzer AB, Davidovitch RI, Egol KA. Use of a "hybrid" locking plate for complex metaphyseal fractures and non- unions about the humerus. Injury 2009;40:240-4.
8. Saragaglia D, Rouchy RC, Mercier N. Fractures of the distal humerus operated on using the Lambda® plate: Report of 75 cases at 9.5 years follow-up. OrthopTraumatolSurg Res 2013;99:707-12.
9. Tejwani NC, Murthy A, Park J, McLaurin TM, Egol KA, Kummer FJ. Fixation of extra- articular distal humerus fractures using one locking plate versus two reconstruction plates: A laboratory study. J

Trauma 2009;66:795-9.

10. Paris H, Tropiano P, ClouetD'orval B, Chaudet H, Poitout DG. Fractures of the shaft of the humerus: Systematic plate fixation. Anatomic and functional results in 156 cases and a review of the literature. Rev ChirOrthopReparatriceAppar Mot 2000;86:346-59.
11. Qing Y, Fang W, Qiugen W, Wei G, Jianhua H, Wu X, et al. Surgical treatment of adult extra- articular distal humeral diaphyseal fractures using an oblique metaphyseal locking compression plate via a posterior approach. Med PrincPract 2012;21:40-45.
12. Meloy GM, Mormino MA, Siska PA, Tarkin IS. A paradigm shift in the surgical reconstruction of extra-articular distal humeral fractures: Single-column plating. Injury 2013;44:1620-4.
13. Capo JT, Debkowska MP, Liporace F, Beutel BG, Melamed E. Outcomes of distal humerus diaphyseal injuries fixed with a single-column anatomic plate. IntOrthop 2014;38:1037-43.
14. Fawi H, Lewis J, Rao P, Parfitt D, Mohanty K, Ghandour A. Distal third humeri fractures treated using the SynthesTM 3.5-mm extra-articular distal humeral locking compression plate: Clinical, radiographic and patient outcome scores. Shoulder Elbow 2015;7:104-9.
15. Jain D, Goyal GS, Garg R, Mahindra P, Yamin M, Selhi HS. Outcome of anatomic locking plate in extraarticular distal humeral shaft fractures. Indian J Orthop 2017;51:86-92.

Conflict of Interest: NIL
Source of Support: NIL

How to Cite this Article

Jain D A, Rahul P, Conrad A, Franco. Treatment of distal humerus extra-articular fractures using a single 3.5mm precontoured locking compression plate. J Kar Orth Assoc. May-Aug 2018; 6(2): 7-11.