Interlaminar Lumbar Epidural Steroid Injections for Pain Relief in Cases of Low Backache due to Disc Prolapse and Canal Stenosis

Sreedhara K Doddery[1], Nishanth Ampar[2]

Abstract

Introduction: Low back pain with or without radicular pain is a common problem with a significant impact on the economic and health status of patients. Various treatment modalities are in use with variable outcome. Epidural injections are one of the most commonly performed interventions to provide early pain relief for low backache with radicular pain. However, the evidence is highly variable with regard to the outcome following the interlaminar epidural steroid injections.

Aim: This study was undertaken to assess the efficacy of epidural steroid injection for providing pain relief in cases of low backache with radiculopathy, due to intervertebral disc prolapse prolapsed intervertebral disc (PID) and canal stenosis.

Methods: Among 77 patients, 69 patients completed the follow-up and were included in the final analysis (48 in PID group and 21 in canal stenosis group). Verbal numeric rating scale (VNRS) and Modified North American Spine Society (NASS) patient satisfaction scores were among the parameters used to evaluate the patients.

Results: The patients from both the groups demonstrated significant improvement in post-injection VNRS scores and showed very good satisfaction based on the NASS patient satisfaction scores, with favorable outcome in terms of pain relief.

Conclusions: Interlaminar lumbar epidural steroid injection is a useful, effective, and safe treatment modality for low back pain with radiculopathy due to lumbar intervertebral disc prolapse and/or canal stenosis.

Keywords: Epidural steroid injection, Intervertebral disc prolapse, Lumbar canal stenosis.

Introduction

Low back pain with or without lower limb radicular pain is the most common problem among acute and chronic pain disorders [1]. It can cause significant morbidity, is often debilitating, and results in significant health care related costs. Intervertebral disc prolapse, disc degeneration, spinal stenosis, and spondylolisthesis are the common the diagnoses for lower back pain, with or without lower limb radicular pain. Various mechanisms for disc-related pain have been described. These include disc degeneration, compression of the nerve roots, or biochemical effects, including inflammation and vascular compromise [2, 3, 4]. Various treatment options, including simple bed rest, analgesia, physiotherapy, epidural steroids, and surgery, have been advocated for management of this condition, with varying degree of success [1]. Most patients with low back ache with radicular pain respond to conservative symptomatic management, with the resolution of pain in a few weeks to months [5]. Epidural steroid injections have had a role to play in the treatment of various spine-related conditions, particularly radiculopathy [6]. Several approaches have been used to access the lumbar epidural space, each of which has its advantages and disadvantages. The lumbar interlaminar approach is the commonly used route, followed by lumbar transforaminal and caudal epidural approaches [7]. The present study assessed the efficacy of epidural steroid injection for providing pain relief in cases of intervertebral disc prolapse and canal stenosis.

[1]Department of Orthopaedics, Prime Medical Centre, Bur Dubai, Dubai.
[2]Department of Orthopaedics, Kasturba Medical College, Manipal Academy of Higher Education, Manipal, Karnataka, India

Address of correspondence :
Dr. Nishanth Ampar,
Kasturba Medical College, Manipal Academy of Higher Education, Manipal, Karnataka, India.
Email: ortho.dr.nishanth@gmail.com

Materials and Methods

Following the approval for the study by the ethical committee, we conducted a prospective study in 77 patients with magnetic resonance imaging (MRI)-proven disc prolapse and spinal canal stenosis, with radicular pain or neurogenic claudication (Table 1). These patients were refractory to various non-invasive methods of treatment, which included adequate bed rest,

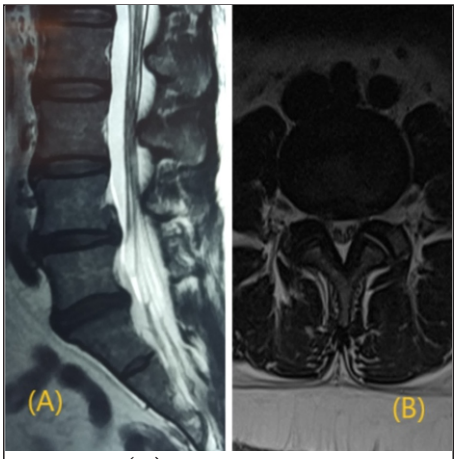

Figure 1: (A) T2W midsagittal section showing cranially migrated disc at L4–L5 (prolapsed intervertebral disc Group); (B) T2W axial magnetic resonance images showing Grade A 2 canal stenosis and moderate lateral canal stenosis (canal stenosis group).

analgesics, and traction. After obtaining the necessary informed consent from the patients, they were administered interlaminar epidural steroid injections and pain relief was assessed after the procedure. The inclusion criteria were MRI findings with disc prolapse (central, paracentral, and foraminal disc and/or canal stenosis (Grade A [A1, A2, A3, and A4] and Grade B), [8] (Fig. 1) with correlated signs and symptoms on clinical examination. The study excluded all the patients with: (1) Motor deficits, (2) segmental instability on radiographs, (3) uncontrolled diabetes mellitus, (4) bleeding disorders, (5) previous lumbar surgeries, (7) far lateral disc prolapse, and (6) Grade C and D canal stenosis [8].

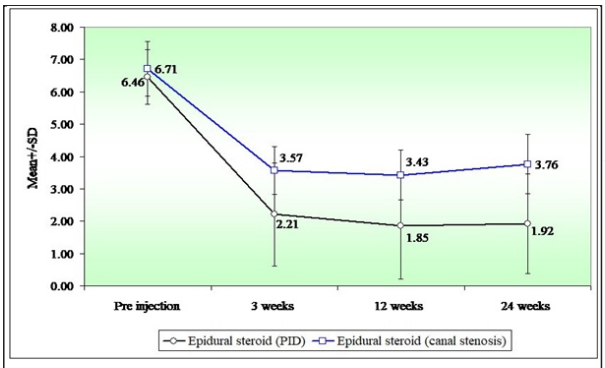

Figure 3: Comparison of verbal numeric rating scale scores at different time points in prolapsed intervertebral disc group and canal stenosis group.

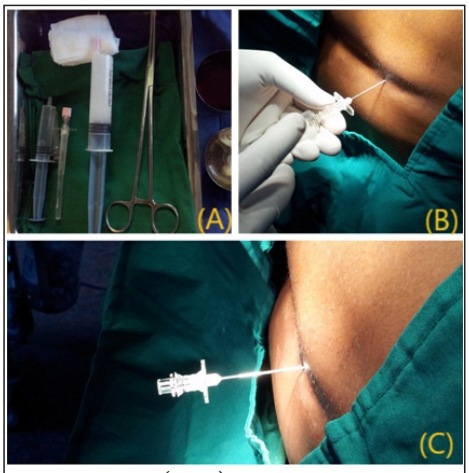

Figure 2: : (A-B) Drug mixture and epidural space identification before injection of the drug.

The patients were divided into two groups: The prolapsed intervertebral disc (PID) group (n = 53) and canal stenosis group (n = 24). Before the injection, variables like rest and walking pain, on a verbal numeric rating scale (VNRS) (0–10 numeric pain intensity scale), straight leg raising test, and findings of motor examination were recorded in all cases. Injection of triamcinolone 80 mg + 2 ml of 2% lignocaine, diluted to a total volume of 20 ml in normal saline, was injected into the epidural space using an interlaminar approach at the L4–L5 interspinous space using an 18-gauge Tuohy needle (Fig. 2). The epidural space was identified by standard non-imaging technique. Patients were subsequently rested in the supine position for 30 min in the recovery room and their vital signs were monitored. All patients were discharged on the day after the procedure. Patients were assessed at intervals of 3, 12, and 24 weeks, during which VNRS and a 4-point Modified North American Spine Society (NASS) patient satisfaction scores (Table 2) were recorded for each patient. Five patients from the PID group and three from the canal stenosis group had to undergo surgery due to worsening of pain or due to onset of motor deficits. These patients were not included in the final analysis. The remaining 48 patients from the PID group and 21 patients from the canal stenosis group were followed up for at least 6 months.

Statistical Analyses

Statistical analyses were performed using IBM Corp. Released 2012. IBM SPSS statistics for Windows, Version 21.0. Armonk, NY: IBM Corp. Wilcoxon matched-pairs tests were used to compare the VNRS scores at different time points, in both the groups, while the Mann-Whitney U-test was applied to compare NASS patient satisfaction scores at the end of 24 weeks among the two groups. Statistical significance was defined as $P \leq 0.05$.

Results

Among the 48 patients analyzed in the PID group, the mean age of patients was 39.8 years (range 29–52 years); 27 were men and 21 were women. Among the 21 patients in the canal stenosis group, the mean age was 59.9 years (range 27–83 years); 12 were men and 9 women. The mean pre-injection VNRS score was 6.46 ± 0.85 in the PID group. The post-injection VNRS scores at 3, 12, and 24 weeks reduced to 2.21, 1.85, and 1.92 respectively, and a mean difference of 4.54 was noted in the VNRS at the pre-injection stage and 24 weeks post-injection ($P < 0.001$) (Table 3). The percentage of change in this group was 70.32%. The VNRS at 12 weeks was the least; however, there was no significant difference in the VNRS scores at 12 weeks and 24 weeks ($P > 0.05$). In the canal stenosis group, the mean pre-injection VNRS score was 6.71 ± 0.85. The post-injection VNRS score at 3, 12, and 24 weeks reduced to 3.57, 3.43, and 3.76, respectively. The mean difference of 2.95 was noted in the VNRS score at pre-injection and the VNRS score at 24 weeks post-injection ($P < 0.001$) (Table

Table 1: Distribution of pathology

Disc prolapse	Number of patients	Incidence (%)
Single level		
L4-L5	21	39.62
L5-S1	17	32.08
L3-L4	3	5.66
Two levels		
L4-L5 and L5-S1	12	22.64
Total	53	100
Canal stenosis (Grades A [A1, A2, A3, and A4] and B) grading of severity of lumbar spinal stenosis [8]		
Single level		
L4-L5	2	8.33
L5-S1	1	4.17
Two Levels		
L3-L4 and L4-L5	5	20.83
L4-L5 and L5-S1	9	37.5
Three levels		
L3-L4, L4-L5, and L5-S1	7	29.17
Total	24	100

4). The percentage of change in this group was 43.97%. The VNRS score was the lowest at 12 weeks. The NASS patient satisfaction scores at the end of 24 weeks were graded as perfect in 7 patients (14.58%), good in 31 patients (64.58%), moderate in 9 patients (18.75%), and bad in 1 patient (2.08%) in the PID group. The NASS patient satisfaction scores indicated that no patients graded this as perfect at the end of 24 weeks, 13 patients (61.9%) graded it as good, 5 patients (23.81%) as moderate, and 3 patients (14.29%) as poor in the canal stenosis group. The PID group had better NASS patient satisfaction scores than did the canal stenosis group at the end of 24 weeks ($P < 0.05$) (Table 5). The mean difference between the pre-injection VNRS and VNRS at 24 weeks was higher in the patients in the PID group (4.54) than in the canal stenosis group (2.95, $P < 0.001$) (Fig. 3). epidural steroid PID and canal stenosis groups in terms of NASS patient satisfaction scores at the end of 24 weeks. One patient had hypotension immediately after the injection, which was managed by intravenous fluids and supportive therapy; the patient recovered within approximately 20 min. No other complications were noted in the study groups.

Discussion

Interlaminar epidural steroid injections are commonly being used to provide pain relief in case of intervertebral disc prolapse and sciatica, with proven short- to long-term benefits in terms of pain relief [1, 2]. Apart from anti-inflammatory properties, the injected material displaces the dura forward and inward, stretching the nerve roots, and causes lysis of neural adhesions. The drug, then, spreads along the epidural space, providing effective pain relief [9]. In a study comparing the efficacy of transforaminal epidural steroid with interlaminar epidural steroid, the authors concluded that interlaminar epidural steroid injections can be as effective as transforaminal epidural steroid injections when performed at the nearest level of lumbar pathology [10]. Various studies have shown a favorable outcome following interlaminar epidural steroid injections in patients with a PID [6, 13]. In our study, the patients demonstrated significant improvement in post-injection VNRS scores and showed very good satisfaction scores based on the modified NASS patient satisfaction scores, implying a favorable outcome of the procedure in terms of pain relief. Paisley et al. studied the dispersal pattern of injectate after interlaminar lumbar epidural steroid injections using lumbar computed tomography epidurography. They concluded that the injectate diffuses throughout the epidural space with nearly uniform circumferential flow, as well as significant rostral and caudal flow. As a result, the amount of drug reaching the target level may be lower due to dispersion in the canal. However, this approach could be useful for multilevel disc prolapse [11, 12]. In view of this, higher volume of the drug may be needed when using the interlaminar route than when using a transforaminal approach. We also included patients with mild-to-moderate spinal canal stenosis and evaluated them separately. The efficacy of injection therapies in spinal canal stenosis has not yet been elucidated and has resulted in mixed outcomes in such patients. Botwin et al. conducted a prospective study on 34 patients who received caudal steroid injections under fluoroscopic guidance. After a follow-up of 6 weeks, 6 months, and 12 months, the pain scores decreased by >50% in comparison with the pre-injection scores. At 12 months, 52% of the patients reported that they were "somewhat better" [14]. Fukusaki et al. did not favor epidural steroid injections for cases of canal stenosis and opined that epidural steroids have no role to play in the management of pain in the same [15]. Friedly et al., in their survey, described that spinal stenosis accounted for 23% of all epidural steroid injections in the U.S Medicare Population [16]. In our series, these patients had a good response to epidural steroid injections; however, it was not as efficacious as that in the PID group. However, only patients with mild-

Table 2: Modified NASS

Score	
Bad	No change of complaints; even worse
Moderate	Epidural steroid helped me, but I won't let this procedure again
Good	Most of the complaints are relieved, and I would again let this procedure if my complaints reappear
Perfect	Epidural steroid satisfied me and fulfilled my expectations.

NASS: North American Spine Society

Table 3: Comparison VNRS scores in PID group at different time points, using the Wilcoxon matched-pairs test

Time points	Mean±SD	Mean difference	SD difference	% of change	*Z*-value	*P* value
Pre-injection/3 weeks	6.46±0.85/2.21±0.74	4.25	0.7	65.81	6.0308	<0.001
Pre-injection/12 weeks	6.46±0.85/1.85±0.77	4.6	0.71	71.29	6.0308	<0.001
Pre-injection/24 weeks	6.46±0.85/1.92±0.92	4.54	0.94	70.32	6.0308	<0.001
3 weeks/12 weeks	2.21±0.74/1.85±0.77	0.35	0.6	16.04	3.2427	<0.01
3 weeks/24 weeks	2.21±0.74/1.92±0.92	0.29	0.8	13.21	2.1519	<0.05
12 weeks/24 weeks	1.85±0.77/1.92±0.92	−0.06	0.67	−3.37	0.5879	0.5566

VNRS: Verbal numeric rating scale, PID: Prolapsed intervertebral disc, SD: Standard deviation

Table 4: Comparison of the VNRS scores at different time points in the canal stenosis group using the Wilcoxon matched-pairs test

Time points	Mean±SD	Mean difference	SD difference	% of change	*Z*-value	*P* value
Pre-injection/3 weeks	6.71±0.85/3.57±1.60	3.14	1.56	46.81	3.823	<0.000
Pre-injection/12 weeks	6.71±0.85/3.43±1.63	3.29	1.55	48.94	3.823	<0.000
Pre-injection/24 weeks	6.71±0.85/3.76±1.55	2.95	1.36	43.97	3.823	<0.000
3 weeks/12 weeks	3.57±1.60/3.43±1.63	0.14	0.57	4	1.0142	0.3105
3 weeks/24 weeks	3.57±1.60/3.76±1.55	−0.18	-0.13	−5.32	1.0987	0.2719
12 weeks/24 weeks	3.43±1.63/3.76±1.55	−0.32	-0.42	−9.71	1.2014	<0.04

VNRS: Verbal numeric rating scale, SD: Standard deviation

Table 5: Comparison of epidural steroid PID and canal stenosis groups in terms of NASS patient satisfaction scores at the end of 24 weeks

Time points	Epidural steroid (PID) (%)	Epidural steroid (canal stenosis) (%)	Total (%)
Bad	1 (2.08)	0 (0.00)	1 (1.45)
Poor	0 (0.00)	3 (14.29)	3 (4.35)
Moderate	9 (18.75)	5 (23.81)	14 (20.29)
Good	31 (64.58)	13 (61.90)	44 (63.77)
Perfect	7 (14.58)	0 (0.00)	7 (10.14)
Total	Chi-square=10.5584	*P*=0.0320*	

*$P<0.05$, PID: Prolapsed intervertebral disc, NASS: North American Spine Society

to-moderate stenosis were included in our study; hence, the true efficacy for the canal stenosis group remains unclear. On comparing the two groups, VNRS scores and NASS patient satisfaction scores were better in patients who received epidural steroid injection for PID than for canal stenosis. The pathogenesis of spinal canal stenosis is multifactorial. In addition to mechanical compression, there can be vascular, biochemical, or biomechanical issues or a combination of these factors causing pain in the patients with canal stenosis. Thus, epidural steroid injections may not be as efficacious in this group as in the prolapsed intervertebral group, where the predominant cause of pain is chemical neuroradiculitis due to inflammation of the nerve roots [1]. Epidural steroid injections, although well-tolerated, are not devoid of complications. Serious complications, such as dural injury (frequency: 2–5%), and symptoms, such as headache and nausea, were reported in a series by Chou et al. [18]. In addition, infectious complications, such as epidural abscesses and septic meningitis, have been reported. Hence, strict monitoring of asepsis is mandatory during the procedure [18]. Wybier et al. studied 12 cases of paraplegia following epidural steroid injection and concluded that the most probable mechanism of this severe, although exceptionally rare complication is due to violation of a radiculomedullary artery, with embolization of macroaggregates of steroids, and subsequent deprivation of the arterial supply of the cord [19]. Although epidural steroid injection is very well tolerated compared with systemic steroids, a few systemic complications have been observed. Manchikanti reported complications such as hyperglycemia and adrenal suppression, in cases of repeated epidural steroid injection in short intervals [20]. We did not encounter any complications in our study. There were no cases of dural puncture or infection or any of the other aforementioned complications in any of the patients in our study.

Conclusion

Interlaminar lumbar epidural steroid injection is a useful, effective, and safe treatment modality for lower back pain with radiculopathy due to lumbar intervertebral disc prolapse and/or canal stenosis. Epidural steroids do provide very good analgesia and even marked pain relief; however, the long-term effect of the procedure must be studied in more detail.

References

1. *Stafford MA, Peng P, Hill DA. Sciatica: A review of history, epidemiology, pathogenesis, and the role of epidural steroid injection in management. Br J Anaesth 2007;99:461-73.*
2. *Onozawa T, Atsuta Y, Sato M, Ikawa M, Tsunekawa H, Feng X, et al. Nitric oxide induced ectopic firing in a lumbar nerve root with cauda equina compression. Clin Orthop Relat Res 2003;408:167-73.*
3. *Mixter WJ, Barr JS. Rupture of the intervertebral disc with involvement of the spinal canal. N Engl J Med 1934;211:210-5.*
4. *Lindahl O, Rexed B. Histologic changes in spinal nerve roots of operated cases of sciatica. Acta Orthop Scand 1951;20:215-25.*
5. *Weber H, Holme I, Amlie E. The natural course of acute sciatica with nerve root symptoms in a double-blind placebo-controlled trial evaluating the effect of piroxicam. Spine (Phila PA 1976) 1993;18:1433-8.*
6. *Stout A. Epidural steroid injections for low back pain. Phys Med Rehabil Clin N Am 2010;21:825-34.*
7. *Pandey RA. Efficacy of epidural steroid injection in management of lumbar prolapsed intervertebral disc: A Comparison of caudal, transforaminal and interlaminar routes. J Clin Diagn Res 2016;10:RC05-11.*
8. *Schizas C, Theumann N, Burn A, Tansey R, Wardlaw D, Smith FW, et al. Qualitative grading of severity of lumbar spinal stenosis based on the morphology of the dural sac on magnetic resonance images. Spine (Phila Pa 1976) 2010;35:1919-24.*
9. *Rezende R, Jacob Júnior C, da Silva CK, de Barcellos Zanon I, Cardoso IM, Batista Júnior JL, et al. Comparison of the efficacy of transforaminal and interlaminar radicular block techniques for treating lumbar disk hernia. Rev Bras Ortop 2015;50:220-5.*
10. *Beyaz SG. Comparison of transforaminal and interlaminar epidural steroid injections for the treatment of chronic lumbar pain. Rev Bras Anestesiol 2017;67:21-7.*

11. *Paisley K, Jeffries J, Monroe M, Choma T. Dispersal pattern of injectate after lumbar interlaminar epidural spinal injection evaluated with computerized tomography. Global Spine J 2012;2:27-32.*

12. *Rabinovitch DL, Peliowski A, Furlan AD. Influence of lumbar epidural injection volume on pain relief for radicular leg pain and/or low back pain. Spine J 2009;9:509-17.*

13. *Ackerman WE 3rd, Ahmad M. The efficacy of lumbar epidural steroid injections in patients with lumbar disc herniations. Anesth Analg 2007;104:1217-22, tables of contents.*

14. *Botwin K, Brown LA, Fishman M, Rao S. Fluoroscopically guided caudal epidural steroid injections in degenerative lumbar spine stenosis. Pain Physician 2007;10:547-58.*

15. *Fukusaki M, Kobayashi I, Hara T, Sumikawa K. Symptoms of spinal stenosis do not improve after epidural steroid injection. Clin J Pain 1998;14:148-51.*

16. *Friedly JL, Comstock BA, Turner JA, Heagerty PJ, Deyo RA, Sullivan SD, et al. A randomized trial of epidural glucocorticoid injections for spinal stenosis. N Engl J Med 2014;371:11-21.*

17. *Chou R, Atlas SJ, Stanos SP, Rosenquist RW. Nonsurgical interventional therapies for low back pain: A review of the evidence for an American pain society clinical practice guideline. Spine (Phila PA 1976) 2009;34:1078-93.*

18. *McGrath JM, Schaefer MP, Malkamaki DM. Incidence and characteristics of complications from epidural steroid injections. Pain Med 2011;12:726-31.*

19. *Wybier M, Gaudart S, Petrover D, Houdart E, Laredo JD. Paraplegia complicating selective steroid injections of the lumbar spine. Report of five cases and review of the literature. Eur Radiol 2010;20:181-9.*

20. *Ridley MG, Kingsley GH, Gibson T, Grahame R. Outpatient lumbar epidural corticosteroid injection in the management of sciatica. Br J Rheumatol 1988;27:295-9.*

Conflict of Interest: NIL
Source of Support: NIL

How to Cite this Article

Doddery S K, Ampar N. | Interlaminar Lumbar Epidural Steroid Injections for Pain Relief in Cases of Low Backache due to Disc Prolapse and Canal Stenosis. | Journal of Karnataka Orthopaedic Association. | Jan-April 2019; 7(1): 19-23.