A Study to Know Short Term Outcome of Tricolumnar Plating in Complex Tibial Plateau Fractures

S. B Kamareddy[1], Pradeep Kumar Natikar[2], Mujtaba Hussain Patel[1,2]

Abstract

Background: Tricolumnar plate fixation in comminuted proximal tibial fractures remains a new concept to have a rigid construct and to improve the functional outcome with dual incision. We performed a retrospective study to evaluate the functional outcome of proximal tibial fracture fixation using tricolumn plating.

Objective: The objective of the study was to study the clinical outcome of internal fixation with tricolumnar plating for the treatment of complex tibial plateau fractures.

Materials and Methods: The study was conducted in tertiary care center, Kalaburagi, over a period of 2 years from June 2017 to June 2019. Twenty patients with complex tibial plateau fractures were treated with tricolumnar plating through posteromedial and anterolateral approaches. There were 12 males and 8 females, with an average age of 45.2 years old (ranged, 32–60 years old). Fourteen patients had injuries in the left side and 6 patients had injuries in the right side. According to Schatzker classification, 14 patients were type V and 6 patients were type VI.

According to the three-column classification, all the patients had injuries of lateral, medial, and posterior columns. All the patients were evaluated using the Oxford Knee Score at 6-month and 1-year follow-up.

Results: The mean interval from injury to operation was 9.4 days (ranged, 6–15 days). The bone union time ranged from 4 to 10 months after operation. According to the results of Oxford Knee Score, 14 patients got an excellent result, 3 good, and 3 moderate.

Conclusion: Tricolumnar plate fixation for the treatment of complex tibial plateau fractures is effective to achieve anatomic reduction, rigid internal fixation, and good functional outcome. Careful soft-tissue handling and employing minimally invasive techniques minimize soft-tissue complications.

Keywords: Tricolumnar plating, Schatzker classification, Oxford Knee Score.

Introduction

Complex tibial plateau fracture management remains clinically challenging and still controversial because these kinds of fractures are mostly highly comminuted, accompanied by severe injuries to the soft tissue and articular cartilage. Luo et al. generated the three-column classification system of the tibial plateau and divided the tibial plateau into three regions (Fig. 1): Lateral column, medial column, and posterior column [1]. Bilateral dual plating is usually recommended as the definite fixation for this kind of fracture [2, 3, 4, 5]. However, this technique sometimes is unlikely to work in fractures with multiplanar articular comminution. This is especially true when there is posterior shearing or a coronal fracture [6, 7]. Computed tomography (CT)-based three-dimensional consideration of the fracture pattern was important in the treatment of complex tibial plateau fractures [8, 9, 10]. In recent years, a "three-column fixation" technique is used to treat the multiplanar complex tibial plateau fractures, which is based on three-dimensional understanding of the fractures. The ideal treatment of high-energy tibial plateau fractures remains controversial. Open reduction and rigid internal fixation achieves the goals of anatomic articular congruity and mechanical alignment restoration, while allowing early knee mobilization. Hence, our study was aimed to evaluate the functional outcome of proximal tibial fracture fixation using tricolumn plating.

[1]Kamareddy Ortho and Trauma Care Centre, Kalaburagi, Gulbarga, Karnataka, India.
[2]Department of Orthopaedics, KBNIMS Kalaburagi, Gulbarga, Karnataka, India.

Address of correspondence :
Dr. Pradeep Kumar Natikar,
KBNIMS Kalaburagi, Gulbarga, Karnataka, India.
E-mail: drpradeepnatikar@gmail.com

Materials and Methods

From June 2017 to June 2019, a comparative prospective cohort study on 20 adult patients. All study participants gave written informed consent for participation.

All skeletally mature patients with Schatzker Type V and VI and AO/OTA type C closed proximal tibial plateau

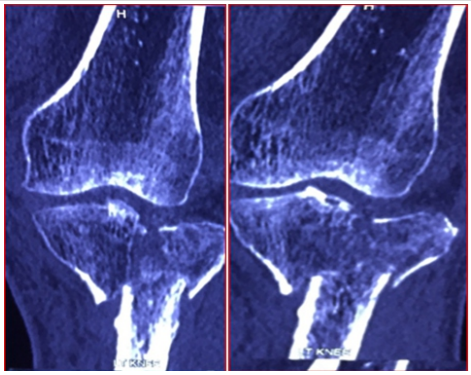

Figure 1: Coronal computed tomography scan indicating both medial, lateral and posterior column are involved.

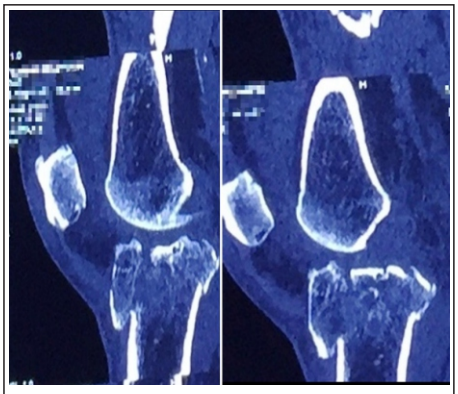

Figure 2: Sagital computed tomography scan indicating both medial, lateral and posterior column are

Figure 3: showing anteroposterior and lateral radiograohs of the left knee showing schatzker type 6 fracture and fibula head fracture.

fractures which was further confirmed with CT scans were included in the study. "Besides Schatzker classification, fractures were also classified using the Lao's three-column concept (Fig. 1)." On the transverse view, the tibial plateau is divided into three areas, which are defined as the lateral column, the medial column, and the posterior column.

A "three-column classification" was used for decision-making. The "three-column fracture" is defined as at least one independent articular fragment in each column. The most common three-column fracture is a traditional "bicondylar fracture" (Schatzker Type V or Type IV) combined with a separate posterolateral articular fragment.

Surgical Approach

All cases were done under combine spinal anesthesia with epidural analgesia and tourniquet application through posteromedial and anterolateral approaches. All primary reduction and final stabilizations were done under image intensifier control.

Postoperative protocol

On day 3, dressing was changed. The 5th day after surgery when pain subsided, physiotherapy was initiated in the form of static quadriceps strengthening exercise for 1 week followed up by passive knee bending for the next week and active knee bending subsequently. Six weeks post-operative, partial weight-bearing on the affected extremity is started. Sixteen weeks later, when X-ray revealed union, full weight-bearing was allowed.

Assessment of outcome

Patients were evaluated by plain radiographs every 6 weekly till fracture union is evident. Fracture union was assessed by cortical continuity and progressive loss of fracture line on subsequent X-rays. One-year post-operative follow-up CT scans were done at final follow-up to record articular subsidence, non-union, and functional status.

Functional outcome was assessed by the Oxford Knee Score. The patients were questioned regarding the degree of pain in the knee during the past week, distance that they are able to walk, any difficulty in toilet activities, any difficulty in getting in and out of a car or bus, getting up from the floor or chair, any limp, ability to kneel and get up, any night pains, ability to do household chores or activities of daily living, climbing up and coming down the stairs, and household shopping. They were also questioned regarding any giving way of the knee. The scores were graded as poor (0–19), moderate (20–29), good (30–39), and excellent (40–48).

Statistical analysis

Data interpretation was done by SPSS® version 21.0, IBM, Armonk, NY, USA. Time of union and other numerical parameters were analyzed by Student's

Oxford Knee score	No of patients	Result
40-48	14	Excellent
30-39	3	Good
20-29	3	Moderate

Figure 4: Immediate postoperative radiographs showing the anatomical reduction and three column fixation.

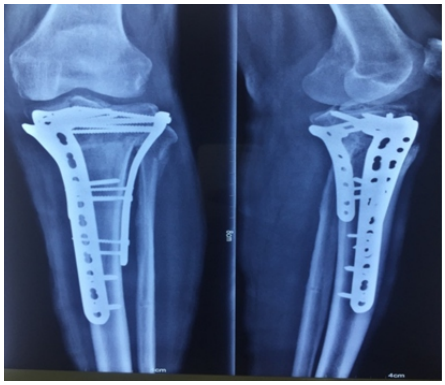

Figure 5: One month postoperative radiographs showing the anatomical reduction and three column fixation.

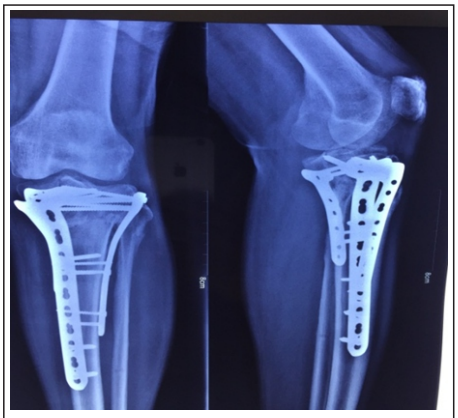

Figure 6: Six month postoperative radiographs showing the anatomical reduction and three column fixation

t-test. Categorical/nominal variables were analyzed by Chi-square test with continuity correction.

Results

According to Schatzker classification, 14 patients were type V and 6 patients were type VI who had been treated in our hospital between June 2017 and June 2019. There were 12 males and 8 females, with an average age of 45.2 years old (ranged, 32–60 years old). Fourteen patients had injuries in the left side and 6 patients had injuries in the right side. All the injuries were a result of road traffic accidents. Hospital stay varied from 7 to 14 days (mean 9 days).

One patient had associated compartment syndrome, underwent fasciotomy, primary internal fixation, and stay suture of the wound, regular dressings and limb elevation were given for 2 weeks and split skin grafting of the fasciotomy wound was done after the 3rd week. Two patients had fractures of contralateral clavicle in one patient and ipsilateral distal end radius fracture in second patient which were treated conservatively. The mean operating time was 150 min. The average blood loss was 75 ml (range: 50 ml–100 ml).

All our patients had union in 4–10 months after operation (average 6 months). All our patients had average knee flexion of 100°. One patient had extension lag of less than 5°. One patient had deep infection managed by I.V antibiotics and regular dressing. One patient had valgus malalignment. Skin necrosis occurred in two patients due to which caused persisting pressure on the distal end of suture line and required secondary suturing.

Functional outcome of our patients was graded by the Oxford Knee Score criteria. Fourteen patients had scores between 40 and 48. Three patients had scores between 30 and 39 and three patients between 20 and 29.

Discussion

Most complex tibial plateau fractures are a result of high-energy injury. Resulting comminution makes interpreting of fracture patterns difficult. Fully understanding these fractures is the basis for successful treatment. Both the Schatzker and AO/Orthopaedic Trauma Association systems classify these fractures according to the appearance on anteroposterior radiographs [11]. Wicky et al. 10 reported a cohort of 42 cases with tibial plateau fractures, which were assessed by plain radiographs and three-dimensional CT separately. As a result, 43% (18 of 42) of the fractures were under evaluated by plain radiographs. On the other hand, such fractures can be difficult to fit into the classification systems currently used, which makes diagnosis and pre-operative planning difficult. Macarini et al. [12] studied 25 cases of tibial plateau fractures. After CT scan, only 48% of the cases had the same classification as before the CT scan and 60% of the cases had changes in the operative plan. Most authors agree that CT scanning adds invaluable information to the treatment of tibial plateau fractures [13]. We think the CT-based "three-column concept" can help surgeons analyze these fractures three dimensionally providing a better approach and fixation methods. To reconstruct a stable and painless mobile knee, it needs expertise and sufficient technical knowledge. These fractures pose challenge for anatomic reduction to maintain the articular congruity, prevent

Figure 7: Active flexion

Figure 8: Active SLRT

Figure 9: Active extension.

varus collapse, and prevent the early onset of the secondary osteoarthritis in these complex tibial plateau fractures.

In our study, males predominate the female with the ratio of 3.75:1, which shows the more active lifestyle involving the high-velocity injury, which are in accordance with the series of 14 patients reported by Eggli et al. [14], in which 10 were male and 4 were female. The management of tibial plateau fractures has improved dramatically over the past 50 years. In the early 1950s, these fractures were treated non-operatively and many surgeons published favorable results by this management.

Road traffic accident is the most common cause of these fractures. Rigid fixation with good articular reduction is an important goal of surgery to get good knee function [15]. Reaching the posteromedial fragment through a single incision causes wide periosteal stripping and extensive muscle dissection and may hamper reduction as well. Dual incisions are better than single incision [16].

Using C-arm helps in achieving indirect reduction and using K-wires as joysticks, we were able to obtain reduction of the articular and metaphyseal fragments without damaging the soft tissues. Using minimally invasive techniques on the medial side to place and fix the plates with screws have helped mitigate soft-tissue complications. The posteromedial plate was slid below the pes anserinus and anteromedial plate was slid under the medial hamstring tendons subperiosteal and resutured back. As we were able to obtain rigid fixation with lateral, postero- and anteromedial plates and thus started knee movements in the immediate post-operative period. This ability to start early aggressive knee rehabilitation has helped us achieve excellent functional outcome in our series, we did not encounter any patient with posterolateral segment.

The use of isolated lateral locking plate and dual plates is still a debate. Patients treated with isolated lateral locking plate had high risk of loss of reduction and increased incidence of malunion [17].

Tricolumnar plating is preferred over other techniques as it has several advantages: Better visualization of fracture fragments, especially posteromedial fragment and articular surface, lateral, medial column, and posterior column is fixed to obtain stability [18].

Our study has certain limitations; first, we have a relatively small sample. Second, follow-up duration is short. There was no post-operative CT scan to evaluate and quantify the reduction.

Conclusion

Three-column plate internal fixation for the treatment of complex tibial plateau fractures through posteromedial and anterolateral approaches is effective to achieve anatomic reduction, rigid internal fixation, and early functional exercise. High-velocity tibial plateau fracture has excellent to good clinical, functional, and radiological outcome. Early mobilization of the joint provides good range of motion. Posteromedial and anteromedial plating provides a buttress to posteromedial and anteromedial fragment and thereby prevents varus collapse. The patients with good soft-tissue cover should undergo anatomical reduction and rigid fixation immediately without deferring time.

References

1. *Luo CF, Sun H, Zhang B, Zeng BF (2010) Three-column fixation for complex tibial plateau fractures. J Orthop Trauma 24(11):683–692. doi:10.1097/BOT.0b013e3181d436f3*
2. *Krieg JC. Proximal tibial fracture: current treatment, results, and problems. Injury. 2003;34:A2–A10.*
3. *Ricci WM, Rudzki JR, Borrelli J. Treatment of complex proximal tibia fractures with the less invasive skeletal stabilization system. J OrthopTrauma. 2004;18:521–527.*
4. *Carlson DA. Posterior bicondylar tibial plateau fractures. J Orthop Trauma. 2005;19:73–78.*
5. *Barei DP, Nork SE, Mills WJ, Complications associated with internal fixation of high-energy bicondylar tibial plateau fractures utilizing a two incision technique. J Orthop Trauma. 2004;18:649–657*
6. *Weil YA, Gardner MJ, Boraiah SB, Posteromedial supine approach for reduction and fixation of medial and bicondylar tibial plateau fractures. J Orthop Trauma. 2008;22: 357–62.*
7. *Barei DP, O'Mara TJ, Taitsman LA, Frequency and fracture morphology of the posteromedial fragment in bicondylar tibial plateau fracture patterns. J Orthop Trauma. 2008;22:176–82.*
8. *Luo CF, Jiang R, Hu CF, Medial double-plating for fracture dislocations involving the proximal tibia. Knee. 2006;13:389–94*
9. *Hackl W, Riedl J, Reichkendler M, Preoperative computerized tomography diagnosis of fractures of the tibial plateau. Unfallchirurg.2001;104:519–523*
10. *Wicky S, Blaser PF, Blanc CH, et al. Comparison between standardradiography and spiral CT with 3D reconstruction in the evaluation,classification and management of tibial plateau fractures. Eur Radiol.2000;10:1227–1232*
11. *Schatzker J, Tile M. The Rationale of Operative Fracture Care, 2nd ed.Berlin: Springer-Verlag; 1996:390–391.*
12. *Macarini L, Murrone M, Marini S, et al. Tibial plateau fractures:evaluation with multidetector-CT. Radiol Med. 2004;108:503–514.*
13. *Bhattacharyya T, McCarty LP 3rd, Harris MB, et al. The posterior shearing tibial plateau fracture: treatment and results via a posterior approach. J Orthop Trauma. 2005;19: 305–310.*
14. *Eggli et al. Unstable Bicondylar Tibial Plateau Fractures: A Clinical Investigation. J Orthop Trauma. 2008; 22: 673-679.*

15. *Su EP, Westrich GH, Rana AJ, Kapoor K, Helfet DL. Operative treatment of tibial plateau fractures in patients older than 55years. Clin Orthop Relat Res 2004;421: 240-8*

16. *Barei DP, Nork SE, Mills WJ, Coles CP, Henley MB, BenirschkeSK. Functional outcomes of severe bicondylar tibial plateau fractures treated with dual incisions and medial and lateral plates. J Bone Joint Surg Am 2006;88: 1713-21*

17. *Pelsar PM. Controversies in the management of tibial plateau fractures. SA Orthopaedic Journal. 2010, 75.*

18. *Zhang Y. Treatment of Complicated Tibial Plateau fractures with Dual Plating via 2 incision technique, Orthosupersite.com. 2012; 35:3.*

Conflict of Interest: NIL
Source of Support: NIL

How to Cite this Article

Kamareddy SB, Natikar PK, Patel MH | A Study to Know Short Term Outcome of Tricolumnar Plating in Complex Tibial Plateau Fractures | Journal of Karnataka Orthopaedic Association | August-September 2020; 8(2): 2-6.