Original Article
Journal of Karnataka Orthopaedic Association | 2021 January-February; 9(1): 20-25

Evaluation of Functional Outcome of AO Type C Distal Humerus Fractures Treated Through Triceps-Splitting Approach

Anand S R[1], Ravi D Narahatti[1]

Abstract

Background: The treatment of intra-articular distal humerus fractures is a subject of continuous debate in the orthopedic literature. They are uncommon, the anatomy is complex, and the bone is frequently comminuted. The treatment of distal humerus fractures has traditionally been performed through a posterior approach and an olecranon osteotomy. This study is aimed to prospectively evaluate the clinical and functional outcomes of the triceps-split approach for treating AO type C distal humerus fractures.

Methods: Twenty-two patients with distal humeral fracture AO/Orthopaedic Trauma Association type C were treated in our institution. They were treated with a triceps-splitting approach. All the fractures were managed with two-column fixation and were evaluated for functional outcome using Mayo Elbow Performance Score (MEPS).

Results: A total of 22 patients were evaluated postoperatively thoroughly for functional outcome using MEPS which showed 11 patients (50%) had excellent, 8 patients (36.36%) had good, and 3 patients (13.64%) had fair outcome. Range of motion was 113.8° (range from 85° to 135°); the elbow flexion averaged 124.5° (range from 112° to 135°); and the deficit of elbow extension 12.6° (range from 0° to 30°).

Conclusion: The use of a triceps-splitting approach as an alternative to olecranon osteotomy to gain access to the distal humerus provided adequate exposure to perform open reduction and internal fixation with fewer complications, avoiding the complications of reconstruction of osteotomy in the osteotomy technique when used judiciously, especially in simple intra-articular fractures (C1 and C2 type fractures) and the outcomes have been satisfactory.

Keywords: Distal humerus fracture; AO/Orthopaedic Trauma Association type C; Triceps-split approach; Mayo Elbow performance score.

Introduction

The distal humerus fractures are relatively uncommon comprising about 2% of all adult fractures and about one-third of humerus fractures [1, 2, 3, 4, 5]. The majority of the distal humerus fractures (96%) have a complex pattern involving both the columns and the articular surface (AO type C injuries) [6]. The treatment of intra-articular distal humerus fractures is subject to continuous debate in the orthopedic literature [7, 8, 9, 10, 11, 12, 13, 14]. They are uncommon, the anatomy is complex, and the bone is frequently comminuted. It explains why these fractures pose a significant challenge for the orthopedic surgeon. The nowadays debate is related to the type of treatment (open reduction and plate osteosynthesis vs. arthroplasty), to the type of plating in case of osteosynthesis (parallel vs. perpendicular), and the surgical approach [9].

Although the posterior approach using the olecranon chevron osteotomy is considered the gold standard [9, 10, 15, 16, 17], the reconstruction of the osteotomy may lead to complications. These complications include delayed union, wound dehiscence, non-union, malunion, hardware failure, and pain secondary to prominent hardware. Alternative approaches to avoid these complications have been reported during the last years, such as the triceps-splitting [18, 19], triceps-reflecting anconeus pedicle [20, 21], the anconeus flap transolecranon approach [22], and the triceps-sparing approach [23].

The triceps split has been used as a standard approach for distal diaphyseal fractures but its use for periarticular fractures has not been well described. To the best of our knowledge, there are very few recent studies evaluating its systematic use for the treatment of distal

[1]Department of Orthopedics, Mysore Medical College and Research Institute, Mysore, Karnataka, India.

Address of correspondence :
Dr. Ravi D Narahatti,
Post Graduate Resident, Department of Orthopedics, Mysore Medical College and Research Institute, Mysore, Karnataka, India.
E-mail: rd.narahatti@gmail.com

Figure 1: Pre-operative X-ray anteroposterior and lateral view showing distal humerus fracture AO Type C1.

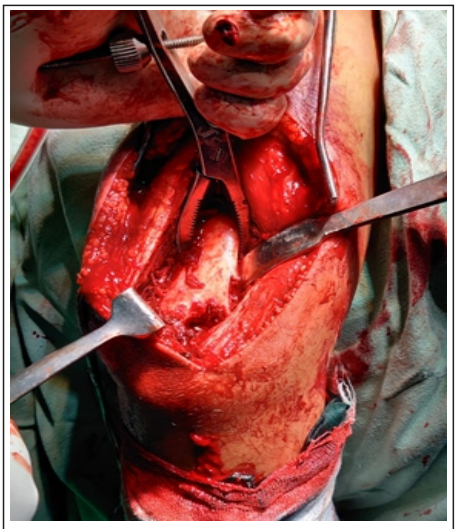

Figure 2: Splitting the triceps tendon in midline, bluntly dissecting the muscle fibers to expose the distal humerus.

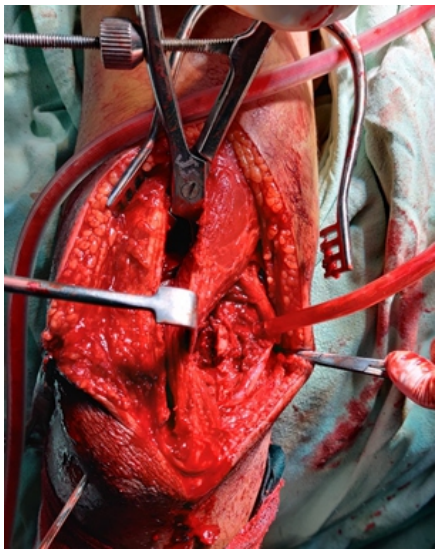

Figure 3: Dissecting out ulnar nerve and securing it.

humerus fractures AO type C in adult patients [24, 25].

Two main questions arise at this point: (1) Does the triceps-splitting approach allow adequate exposure for treating these fractures? and (2) What are the results and associated complications related to this approach for the treatment of distal humerus fractures? Therefore, we conducted this prospective study using the triceps-splitting approach to treat AO type C fractures to study the outcome and complications associated with it.

Methods

All the patients with distal humerus fractures who presented to the Department of Orthopaedics, in our institute between January 2018 and June 2019, were considered for the study. They were subjected to the inclusion and exclusion criteria of the study and a total of 22 patients qualified to be included in the study.

Inclusion criteria

The following criteria were included in the study:

1. AO/Orthopaedic Trauma Association (OTA) Type C fracture.
2. Age above 18 years of age.

Exclusion criteria

The following criteria were excluded from the study:

1. AO/OTA Type A and B fracture.
2. Radiological or clinical signs of any arthritis.
3. Open fractures.
4. Pathological fractures.
5. Associated other fractures of the same limb.

After clinical assessment and hemodynamic stabilization, the patients underwent routine blood investigations and radiographs of the elbow taken in anteroposterior (AP) and lateral view (Fig. 1). Apart from these views routinely, traction view and oblique views were taken. Fractures were classified based on plain injury radiographs, AO/OTA classification. After complete workup, patients were operated within 3 days. All fractures were treated using a triceps-splitting approach and two-column fixation.

Surgical technique

For the triceps-splitting approach, the patient is placed in a prone or lateral decubitus position. In a prone position, abduct arm to 90°, allowing the elbow to flex and forearm to hang over the side of the table. In the lateral decubitus position, the shoulder was placed at 90° flexion and the elbow at 90° flexion. The entire arm and axilla are prepped, and a sterile tourniquet is used. Intraoperative fluoroscopy traction and oblique views were taken apart from AP and lateral views.

A longitudinal midline incision over the posterior aspect with a slight radial deviation over the olecranon was used. The triceps is divided in its midline. In case of tears in the extensor mechanism, they are incorporated into the surgical incision. If the tears are distant from the midline, they are simply repaired, and the midline approach is used.

After splitting the tendon in line with its fibers, the underlying muscle fibers were bluntly dissected exposing the capsule and the fat pad in the olecranon fossa. The capsule was released from the olecranon underneath the tendon insertion and the deep soft tissues reflected medially to expose the olecranon fossa and proximal part of the trochlea (Fig. 2). Palpate the ulnar nerve as it lies in the bony groove on the back of medial epicondyle and incise the fascia overlying it to expose it. Dissect out the ulnar nerve and pass tapes around it so that it can be identified at all times (Fig. 3).

If a more distal exposure was necessary, the lateral part of the triceps tendon was

Figure 4: Orthogonal plate fixation (lateral plate placed posteriorly and medial plate placed medially).

Figure 5: K-wires used to manipulate and temporarily fix the fragments.

Figure 6: Triceps closed as a single layer.

released from the olecranon in continuity with the anconeus muscle and reflected laterally while carefully protecting the lateral collateral ligament complex. After adequate exposure, and reduction of the fracture, the plates were placed on the respective column by mobilization of the triceps muscle. In general, the lateral plate is placed posteriorly and the medial plate is placed medially (orthogonal fixation) (Fig. 4). When needed, additional manipulating systems and K-wires were used (Fig. 5). Supplemental bone grafting was done based on the degree of comminution, quality of bone, bone loss, and soft-tissue integrity.

If the fracture extends into the humeral shaft, or if the fracture is segmental, the posterior approach is easily extended proximally with care taken to identify the radial nerve and accompanying vessels. Closure is accomplished in layers. The triceps is closed as a single layer after tourniquet release and hemostasis (Fig. 6). A drain is used infrequently.

Postoperatively, the patients were splinted for 2 weeks. After this time, they were allowed to begin passive range of motion exercises. After 12 weeks, strengthening exercises and therapy were advanced, as indicated by healing.

Clinical evaluation

The patients were evaluated at 2, 6, 12, 24, and 48 weeks. At 48 weeks (1 year) follow-up, patients elbow pain, motion, stability, and function were assessed according to the Mayo Elbow Performance Score (MEPS). The MEPS ranges from 5 to 100. A score over 90 is considered excellent, between 75 and 89 is good, and between 60 and 74 is fair, and a score under 60 is poor.

Radiographic evaluation

Radiographs of the elbow were taken at the 2nd week and at the 2nd, 6th, and 12th month of follow-up. In all cases, the elbow was studied in AP and lateral views. A final radiograph was taken at the last clinical visit when the follow-up was at least 12 months (Fig. 7). The radiographs were evaluated to determine union, maintenance of the reduction, and implant failure. Apart from these, radiological parameters such as trochlear axis in AP view and distal humeral angle in lateral view were assessed.

Statistical methods

Statistical analysis of this study was done using SPSS version 20 (trial version). Functional outcome was considered as the primary outcome variable. Descriptive analysis was carried out by mean and standard deviation for quantitative variables, frequency, and proportion for categorical variables. The Chi-square test was used to calculate statistical significance. Asymp. sig (P value) $P < 0.05$ was considered statistically significant.

Table 1: Age distribution.

Age group (in years)	No. of cases	Percentage	Mean age	Maximum age	Minimum age
18–30	2	9	44.04±10.43	68	20
31–45	10	45.4			
46–60	8	36.36			
>60	2	9			

Results

A total of 22 patients (14 males and 8 females) were evaluated postoperatively thoroughly for functional outcome. Their mean age was 44.04 ± 10.43 years (minimum age was 20 years and the maximum age was 68 years) (Table 1). In most of the cases, the mechanism of

Table 2: Mode of injury.

	No. of cases	Percentage
Fall	8	36.36
Road traffic accident	14	63.63

Table 3: Fracture type.

Fracture type	No. of cases	Percentage
C 1	4	18.18
C 2	14	63.63
C 3	4	18.18

Figure 7: Twelve months post-surgery follow-up X-ray anteroposterior and lateral view.

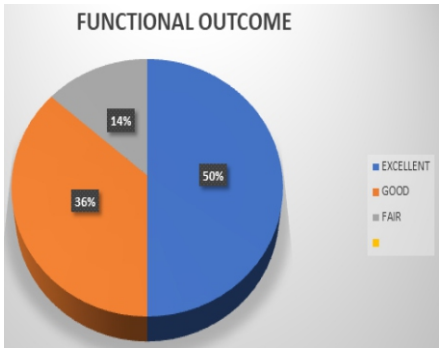

Figure 8: Pie chart showing final functional outcome based on the Mayo Elbow Performance Score.

injury was due to a road traffic accident (63.3%) (Table 2). The most common side of injury was right-sided. The fractures were classified using the AO classification scheme for distal humerus fractures. In our study, most of the cases belong to AO/OTA classification Type C 2(63.3%) (Table 3). The mean time for fracture union was 14.6 ± 3.55 weeks. All cases were operated within 1 week of trauma. The operating time was 1.30–2 hr.

The total range of motion was 113.8° (range from 85° to 135°); the elbow flexion averaged 124.5° (range from 112° to 135°); and the deficit of elbow extension 12.6° (range from 0° to 30°). Overall, 80% of the patients had an arc of motion >100°, and 35% had an arc >120°. By 12 weeks, 8 fractures (36.36%) were considered healed, and by 18 weeks, 20 fractures had healed (91%). And by 24 weeks, all fractures (100%) were healed (Table 4). Functional outcome evaluated using MEPS with a mean score of 82.95 ± 10.74, which showed 11 patients (50%) had excellent, 8 patients (36.36%) had good, and 3 patients (13.64%) had fair outcome (Fig. 8) and it was significant ($p<0.05$). Excellent and good outcomes were consistent with C1 and C2 type fractures and the fair outcome was consistent with C3 type fractures. Out of four cases of C3 type fractures, one case had malreduction of the trochlea and one case had angulation at the fracture site, but the functional outcome was fair in all these cases. Triceps strength, measured with manual clinical testing, was at least four-fifths for all the patients. This was not compared with contralateral extremity strength. There were no extensor mechanism failures, and there was no instance of transient ulnar nerve palsy. One patient presented with a superficial infection caused by Pseudomonas aeruginosa, which was successfully treated with intravenous antibiotics without the need for surgical debridement. No deep infection was documented.

Table 4: Time for union.

No. of weeks	No. of cases	Percentage	Mean time of union	Maximum	Minimum
By 12 weeks	8	36.36	14.6±3.55	24	11
12–18 weeks	12	54.54			
18–24 weeks	2	9			

Discussion

The clinical outcome for distal humerus fractures likely is more dependent on the fracture pattern and ability to attain anatomic reduction and stable fixation than on the surgical approach used [26, 27, 28, 29, 30]. Each described surgical approach has potential advantages and disadvantages. The olecranon osteotomy-related complications, including hardware failure and irritation, reportedly occur at a rate of 27–80% [27, 30, 31, 32]. Furthermore, the rate of osteotomy nonunion reportedly is 0–15% [27, 29, 31].

According to a cadaver study by Wilkinson both osteotomy, triceps reflecting and triceps splitting approaches provided sufficient exposure to the medial and lateral columns to allow plate fixation, but none of them allowed visualization of the anterior articular surface of the trochlea or the radial head [33]. The downside of using an osteotomy is that the plate may cause skin irritation and the osteotomy may not heal, causing reoperations [33].

The triceps split has been used as a standard approach for distal diaphyseal fractures but its use for periarticular fractures has not been well described. There are very few recent studies evaluating its systematic use for the treatment of distal humerus fractures AO type C in adult patient.

In the present study of 22 patients, after a 1-year follow-up, all the fractures healed, and the functional outcome using MEP scores, with a mean score of 82.95 ± 10.74, which showed 11 patients (50%) had excellent, 8 patients (36.36%) had good, and 3 patients (13.64%) had fair

outcome (Fig. 8) and it was significant ($P < 0.05$). The outcome obtained in the present study of 22 elbows is comparable to that of many other series using the olecranon osteotomy [9, 16] but avoiding the complications related to the osteotomy.

In our study, a triceps-splitting approach was found to afford adequate exposure to distal humerus fractures and to allow for the proximal extension when the fracture had a proximal extension. However, visualization of the distal articular surface may not be easy and simple as in olecranon osteotomy, but the positioning of the patient to allow for hyperflexion of the elbow will allow for adequate visualization.

Our study had arcs of motion comparable with those reported in the literature. The expected range is between 0° and 15° of extension to between 100° and 130° of flexion. Our study results compare favorably. In cases with restricted arcs of motion, it seems paramount that patients begin post-operative physiotherapy early.

The limitations of our study include the limited number of cases and the absence of a control group treated using the olecranon osteotomy as the coronal plane fractures of the distal articular surface and metaphyseal comminution are better addressed with olecranon osteotomy. Another limitation of the study is the absence of objective quantification of muscle strength both for flexion and extension of the elbow.

Conclusion

The use of a triceps-splitting approach as an alternative to olecranon osteotomy to gain access to the distal humerus provided adequate exposure to perform open reduction and internal fixation with fewer complications, avoiding the complications of reconstruction of osteotomy in the osteotomy technique when used judiciously, especially in simple intra-articular fractures (C1 and C2 type fractures) and the outcomes have been satisfactory.

References

1. Helfet DL, Schmeling GJ. Bicondylar intra-articular fractures of the distal humerus in adults. Clin Orthop Relat Res 1993;292:26-36.
2. Gupta R, Khanchandani P. Intercondylar fractures of the distal humerus in adults: A critical analysis of 55 cases. Injury 2002;33:511-5.
3. Kundel K, Braun W, Wieberneit J, Rüter A. Intraarticular distal humerus fractures. Factors affecting functional outcome. Clin Orthop Relat Res 1996;332:200-8.
4. Robinson CM, Hill RM, Jacobs N, Dall G, Court-Brown CM. Adult distal humeral metaphyseal fractures: Epidemiology and results of treatment. J Orthop Trauma 2003;17:38-47.
5. Rose SH, Melton LJ, Morrey BF, Ilstrup DM, Riggs BL. Epidemiologic features of humeral fractures. Clin Orthop Relat Res 1982;168:24-30.
6. McCarty LP, Ring D, Jupiter JB. Management of distal humerus fractures. Am J Orthop (Belle Mead NJ) 2005;34:430-8.
7. Ali M, Hassanin EY, El-Ganainy AE, Abd-Elmoa T. Management of intercondylar fractures of the humerus using the extensor mechanism-sparing paratricipital posterior approach. Acta Orthop Belg 2008;74:747-52.
8. Athwal GS, Hoxie SC, Rispoli DM, Steinmann SP. Precontoured parallel plate fixation of AO/OTA Type C distal humerus fractures. J Orthop Trauma 2009;23:575-80.
9. Charissoux JL, Mabit C, Fourastier J, Beccari R, Emily S, Cappelli M, et al. Comminuted intra-articular fractures of the distal humerus in elderly patients. Rev Chir Orthop Reparatrice Appar Mot 2008;94:36-62.
10. Coles CP, Barei DP, Nork SE, Taitsman LA, Hanel DP, Henley MB. The olecranon osteotomy: A six-year experience in the treatment of intraarticular fractures of the distal humerus. J Orthop Trauma 2006;20:164-71.
11. Elhage R, Maynou C, Jugnet PM, Mestdagh H. Long term results of the surgical treatment of bicondylar fractures of the distal humerus extremity in adults. Chir Main 2001;20:144-54.
12. Gofton WT, Macdermid JC, Patterson SD, Faber KJ, King GJ. Functional outcome of AO Type C distal humeral fractures. J Hand Surg 2003;28:294-308.
13. Rubberdt A, Surke C, Fuchs T, Frerichmann U, Matuszewski L, Vieth V, et al. Preformed plate-fixation system for Type AO 13C3 distal humerus fractures: Clinical experiences and treatment results taking access into account. Unfallchirurg 2008;111:308-22.
14. Liu JJ, Ruan HJ, Wang JG, Fan CY, Zeng BF. Double-column fixation for Type C fractures of the distal humerus in the elderly. J Shoulder Elbow Surg 2009;18:646-51.
15. Ring D, Gulotta L, Chin K, Jupiter JB. Olecranon osteotomy for exposure of fractures and nonunions of the distal humerus. J Orthop Trauma 2004;18:446-9.
16. Werner CM, Ramseier LE, Trentz O, Heinzelmann M. Distal humeral fractures of the adult. Eur J Trauma 2006;32:264-70.
17. Wong AS, Baratz ME. Elbow fractures: Distal humerus. J Hand Surg Am 2009;34:176-90.
18. McKee MD, Kim J, Kebaish K, Stephen DJ, Kreder HJ, Schemitsch EH. Functional outcome after open supracondylar fractures of the humerus. J Bone Joint Surg Br 2000;82:646-51.
19. Silva DM, de Los Santos RM, Ramos MA, Pérez CG.Functional results of two different surgical approaches in patients with distal humerus fractures Type C (AO). Acta Ortop Mex 2008;22:26-30.
20. O'Driscoll SW. The triceps-reflecting anconeus pedicle (TRAP) approach for distal humeral fractures and nonunions. Orthop Clin North Am 2000;31:91-101.
21. Ozer H, Solak S, Turanli S, Baltaci G, Colakoglu T, Bolukbasi S. Intercondylar fractures of the distal humerus treated with the triceps-reflecting anconeus pedicle approach. Arch Orthop Trauma Surg 2005;125:469-74.
22. Athwal GS, Rispoli DM, Steinmann SP. The anconeus flap trans olecranon approach to the distal humerus. J Orthop Trauma 2006;20:282-5.
23. Ek ET, Goldwasser M, Bonomo AL. Functional outcome of complex intercondylar fractures of the distal humerus treated through a triceps-sparing approach. J Shoulder Elbow Surg 2008;17:441-6.

24. Ziran BH, Smith WR, Balk ML, Manning CM, Agudelo JF. A true triceps-splitting approach for treatment of distal humerus fractures: A preliminary report. J Trauma 2005;58:70-5.

25. Hallgren HB, Svernlöv PT, Nestorson J, Adolfsson L. Triceps split: A safe and useful approach for distal humeral fractures. Biomed J Sci Tech Res 2020;24:18617-24.

26. Holdsworth BJ, Mossad MM. Fractures of the adult distal humerus: Elbow function after internal fixation. J Bone Joint Surg Br 1990;72:362-5.

27. Jupiter JB, Neff U, Holzach P, Allgower M. Intercondylar fractures of the humerus. An operative approach. J Bone Joint Surg Am 1985;67:226-9.

28. Mueller ME, Allogower M, Schneider R, Willnegger H. Manual of Internal Fixation: Techniques Recommended by the AO Group. 3rd ed. Heidelberg: Springer; 1990. p. 180.

29. Safran O, Mosheiff R, Segal D, Liebergall M. Surgical treatment of intercondylar fractures of the humerus in adults. Am J Orthop (Belle Mead NJ) 1999;28:659-62.

30. Wildburger R, Mahring M, Hofer PH. Supraintercondylar fractures of the distal humerus: Results of internal fixation. J Orthop Trauma 1991;5:301-7.

31. Macko D, Szabo R. Complications of tension-band wiring of olecranon fractures. J Bone Joint Surg Am 1985;67:1396-401.

32. Pierce TD, Herndon JH. The triceps preserving approach to total elbow arthroplasty. Clin Orthop Relat Res 1998;354:144-15.

33. Wilkinson JM, Stanley D. Posterior surgical approaches to the elbow: A comparative anatomic study. J Shoulder Elbow Surg 2001;10:380-2.

Conflict of Interest: NIL
Source of Support: NIL

How to Cite this Article

Anand SR, Narahatti RD | Evaluation of Functional Outcome of AO Type C Distal Humerus Fractures Treated Through Triceps-Splitting Approach | Journal of Karnataka Orthopaedic Association | January-February 2021; 9(1): 20-25.