Case Report | Journal of Karnataka Orthopaedic Association | 2022 August-September; 10(2): 44-47

Revascularization and Reconstruction of a Near Total Amputation of Foot

Latheesh Leo[1], Akhil X. Joseph[1]

Abstract

Case: A 23-year-old male presented with a history of road traffic accident, 8 hours post injury. He was diagnosed to have a Type 3C open fracture with near total amputation at the level of distal third of leg (MESS score 10). He underwent tendon repair, neurovascular repair and ex-fix application. On post-op day 5 he developed skin necrosis and underwent an anterolateral flow-through free flap. 2 months later, after a complete soft tissue recovery, a limb reconstruction system was applied and proximal corticotomy was done, with regular distraction at 1 mm/day until limb length was achieved. 11 months post injury he made a complete bony and soft tissue recovery.

Conclusion: Traumatic amputations are more common among the younger population as it is a result of high velocity road traffic accidents. An amputated limb not only physically impairs a patient but is also a psychological hurdle to overcome. Despite a MESS score of 10, in our case study we managed to salvage a foot, that had undergone near total amputation, 8 hours post injury, with a complete soft tissue and bony recovery. With improved survival and functional outcomes of replanted limbs, replantation should be a high priority as opposed to primary amputation in cases of total or subtotal lower extremity amputations.

Keywords: Near Total Amputation Foot, Revascularisation, Reconstruction, Limb Lengthening, Alt Free Fap

Introduction

Lower extremity traumatic amputations are not infrequent injuries in the modern motorised world- a consequence of high-velocity motor vehicle accidents. Optimal treatment of these patients have long been debated, although current literature shows strong support for primary revision amputation and prosthetic fitting [1-3]. Revision amputations and prostheses come with their own complications and drawbacks, including neuromas, stump problems, substantial financial strains, and derangement of the patient's body self-image [4]. Revascularization of lower extremity amputations is an infrequently reported procedure, and has been a subject of debate since the beginning of microvascular surgery, with the first case being reported by H. R. Magee and W. R. Parker in 1969 [5]. Although existing literature cites mixed results, the management of massive lower limb injuries discourages replantation in view of high complication rates, protracted treatment time, high economic costs, and marginally functional results [6, 7]. We report a case of near total amputation of the foot following a road traffic accident that presented to us 8 hours post injury.

Case Presentation

A 23-year-old male patient presented with a history of Road traffic accident, 8 hours post injury. He sustained an injury to the lower third of the left leg and complained of pain, deformity, and an associated open wound around the left ankle. He also complained of complete loss of sensation in the left foot, distal to the wound. On primary evaluation, we observed an obvious deformity at the lower third of the left leg and a lacerated wound extending circumferentially at the same level, sparing a region of intact skin over the posterolateral aspect, with exposed cut ends of the tendons of flexor hallucis longus, flexor digitorum longus, tibialis posterior and the tendoachilles. The foot appeared pale and was cold on palpation, with absent movements and sensation. Peripheral

[1]Department of Orthopaedic Surgery, Father Muller Medical College Hospital, Kankanady, Mangalore, Karnataka, India.

Address of Correspondence :
Dr. Akhil Xavier Joseph,
Department of Orthopaedic Surgery, Father Muller Medical College Hospital,
Kankanady, Mangalore, Karnataka, India.
E-mail: akhilxj@gmail.com

Submitted: 28-03-2022; Reviewed: 16-04-2022; Accepted: 14-06-2022; Published: 10-09-2022

Journal of Karnataka Orthopaedic Association | Available on www.jkoaonline.com | DOI: https://doi.org/10.13107/jkoa.2022.v10i02.053

Figure 1: Patient on primary evaluation with a Type 3C open fracture of distal third of leg and a CT-angiogram confirming compromised vascularity.

pulses, namely, the dorsalis pedis, posterior tibial and anterior tibial pulsations were absent, and the toes showed no capillary refill nor capillary bleeds on pin prick. His MESS score was 10.

A radiological evaluation was done, with an x-ray of the left leg, and CT-Angiogram of the left lower limb. The x-ray showed a segmental fracture in the distal third of the tibia and a transverse fracture of the distal third of fibula. His CT-Angiogram was reported as absent blood flow in the distal leg arteries, namely, anterior tibial artery, posterior tibial artery and peroneal artery. He was then counselled regarding the prognosis of his injury and planned for surgical debridement, external fixator application, tendon repair and neurovascular repair.

Under spinal anaesthesia a wound was debrided, and the tibia was shortened by 5 cm. Schanz pins were applied in an ankle joint spanning, uniplanar manner and external fixator frame was connected. Finally, a soft tissue repair was done starting with the tendons, namely, Flexor hallucis longus, Flexor digitorum longus, Tibialis posterior using a four strand Gelberman's technique core stitch and epitenon sutures. Partial tear of tendoachilles was noted and repaired. Under

Figure 2: Status-post foot replantation and stabilization with external fixator with blackish discolouration over medial aspect.

microscope guidance the deep veins, the venae comitantes of the anterior and posterior tibial arteries, and finally the anterior tibial artery and the posterior tibial artery was repaired. Wound margins were approximated, and a split thickness skin graft was used to close a defect laterally. The vascular repair was confirmed with a positive doppler signal, before finally applying a sterile dressing and immobilizing the limb in a posterior Plaster of Paris, below-knee slab.

The patient was started on anticoagulants and routine post-operative care was administered. Post-operatively, his foot showed signs of recovery with capillary perfusion, warmth and capillary bleed on pin prick. On post-op day 5, a blackish discolouration over the medial aspect of distal leg was noted (Figure 2), for which we decided to re-explore the wound and planned for an Anterolateral thigh flow through flap cover.

Under spinal anaesthesia, he underwent an anterolateral thigh flow through free flap. A 30 x 15 cm flap was harvested from the right thigh and the pedicle consisted of the descending branch of the lateral circumflex femoral artery with its bifurcation into both the Vastus lateralis and Rectus femoris. The branch to the Vastus lateralis was dissected and perforators to the flap were preserved, while the branch to the rectus femoris was cut proximally. The flap was then anastomosed to the Posterior tibial artery of the left leg, with an end-to-end anastomosis of the branch to the vastus lateralis and the proximal cut end of the posterior tibial artery, followed by an end-to-end anastomosis of the branch to Rectus femoris and the distal cut end of Posterior tibial artery. The accompanying deep and superficial veins were also anastomosed, and the flap was sutured to the

Figure 3: Status-post debridement and flow through ALT free flap

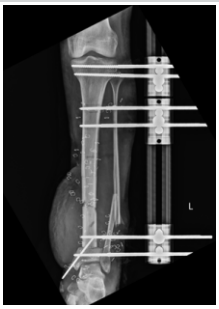

Figure 4: Limb reconstruction system application

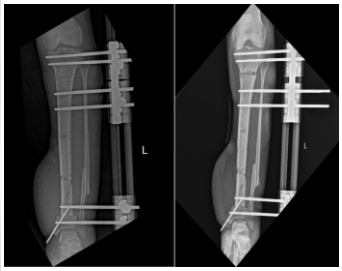

Figure 5: Proximal corticotomy with gradual distraction at 1 week.



Figure 6: Distraction at 1, 2 and 3 months post corticotomy with evident osteogenesis.

Figure 7: Post LRS removal and PTB cast application

defect. Vascularity was confirmed with a doppler, and a sterile dressing was applied. An additional frame was added to the existing external fixator, offloading the leg, and the patient was shifted to the post-operative ICU for recovery (Figure 3).

Patient was once again started on anticoagulants and monitored for flap vascularity. Flap showed healthy uptake and signs of perfusion with good doppler signal, capillary bleeds on scratch test, and no signs of venous congestion. He was then shifted to the ward where regular wound dressings were done, and an ankle-foot orthosis was applied.

One month post-operatively, he underwent external fixator removal and Limb reconstruction system (LRS) application under spinal anaesthesia (Figure 4). He was on regular follow-up on an outpatient basis and wound dressings were continued as taught, at home.

After a complete soft tissue recovery, over a month, he underwent proximal tibial metaphyseal corticotomy of left tibia under spinal anaesthesia. One week post-operatively, distraction was started at a rate of 1 mm per day and distraction was confirmed at the corticotomy site radiographically (Figure 5). Patient was taught how to distract the LRS system, at a rate of 0.25 mm 6 hourly, and was discharged to continue distraction daily at home.

Figure 8: Complete bony and soft tissue recovery with an independently ambulating patient.

He was on regular follow up on an out-patient basis, monthly, where radiographs were taken at each visit and distraction osteogenesis was monitored. On achieving 5.5 cms of distraction, adequate limb length was restored, and distraction was discontinued.

Adequate bony union was seen on radiographs, and he underwent LRS removal, and a Patellar tendon bearing cast was applied.

Finally, 11 months post injury the cast was removed, a repeat x-ray was done, and he had made a complete bony and soft tissue recovery.

Discussion

Literature suggests that most lower limb amputations are below the knee level [8]. We have described a case of near total amputation of the distal leg, focusing on the management and outcome. Traumatic amputations from road traffic accidents have more damage than clean-cut wounds. The bone edges are less viable, and bone shortening is usually required during debridement, as in our case.

Five days post-vascularization, we noted skin necrosis around the wound, as is expected for avulsion and crush injuries [9]. The incidence of soft tissue necrosis and deep infections have been reported to be as high as 90% and 17%, respectively8 often requiring a secondary procedure for wound coverage9. In our case, we used a free flow anterolateral thigh flap with the vastus lateralis muscle. The flap was anastomosed to the Posterior tibial artery of the left leg, in an end-to-end anastomosis of the branch to the vastus lateralis to the proximal end of the posterior tibial artery, followed by an end-to-end anastomosis of the branch to Rectus femoris and the distal cut end of Posterior tibial artery. The accompanying deep and superficial veins were also anastomosed.

Since the start of replantation surgeries, attempts at lower limb replantation have resulted in many complications8. Kutz et al.

[11] in 1983 reported a 33% success rate in his case series of nine patients who underwent replantation of the leg. Over the years with advanced surgical techniques and facilities we have seen a noticeable improvement in the survival rate and outcomes of replantation surgeries. Two decades later, in 2002, Battiston et al. [12] reported a 100% success rate of lower extremity replantation in nine patients. Similarly, Hierner et al. [13] in 2005 reported a 62.5% success rate in 15 replantation's, and Cavadas et al. [8] in 2009, reported a 100% success rate in 13 lower leg amputations who underwent replantation. Likewise, trends have shifted from a tendency to primarily amputate [10] to a more favoured attempt at replanting the limb at all costs.

It was previously believed that the tibial nerve repair to achieve plantar sensation was the most important factor when considering replantation. However, in 2005, Bosse et al. [10] concluded that, functional outcomes did not differ between salvaged limbs and amputated limbs. Standard tibial nerve repair following limb salvage showed good results in regaining plantar sensations [8, 11]. We used an external fixator for more structural strength. Perfect rigidity or anatomical correctness of the bone is not as important as vessel repair, and the latter should not be sacrificed for the former [9].

The indications for replantation versus amputation of the lower extremity are still under debate. The outcomes predicted by the Limb Salvage Index or Mangled Extremity Severity Score10 cannot be applied universally to all cases, and there is no prediction method employed universally [10, 12]. This is seen particularly in this case, wherein, although literature suggests amputating limbs with a MESS score of more than 7, we managed to successfully salvage the limb with a score of 10.

Conclusion

Traumatic amputations are more common among the younger population as it is a result of high velocity road traffic accidents. An amputated limb not only physically impairs a patient but is also a psychological hurdle to overcome. With improved survival and functional outcomes of replanted limbs, replantation should be a high priority as opposed to primary amputation in cases of total or subtotal lower extremity amputation.

Declaration of patient consent: The authors certify that they have obtained all appropriate patient consent forms. In the form, the patient has given his/her consent for his/her images and other clinical information to be reported in the Journal. The patient understands that his/her name and initials will not be published, and due efforts will be made to conceal his identity, but anonymity cannot be guaranteed.

Conflict of interest: Nil **Source of support:** None

References

1. Bondurant FJ, Colter HB, Buckle R, Miller-Crotchett P, Browner BD. The medical and economic impact of severely injured lower extremities. J Trauma 1988;28:1270–1273.
2. Helfert DL, Howy T, Sanders R, Johansen K. Limb salvage versus amputation. Clin Orthop Relat Res. 1990;256:80– 86.
3. Hansen ST Jr. Overview of the severely traumatized lower limb reconstruction versus amputation. Clin Orthop Relat Res. 1989;243:17–19.
4. Gayle LB, Lineaweaver WC, Buncke GM, et al. Lower extremity replantation. Clin Plast Surg. 1991;18:437–447.
5. Magee, H. R., and Parker, W. R., Medical Journal of Australia, 1972, 1, 751.
6. Robertson PA. Prediction of amputation after severe lower limb trauma. J Bone Joint Surg (Br.) 1991;73:816–818.
7. Cavadas PC, Landin L, Iban˜ez J. Temporary catheter perfusion and artery: Last sequence of repair in macro-replantations. J Plast Reconstr Aesthet Surg. (in press)
8. Cavadas PC, Landin L, Ibanez J, et al. Infrapopliteal lower extremity replantation. Plast Reconstr Surg. 2009;124:532–9.
9. Cavadas PC, Thione A. Lower limb replantation. In: Salyapongse AN, Poore S, Afifi A, et al., editors. Extremity replantation: a comprehensive clinical guide. New York: Springer; 2015. pp. 145–59.
10. Bosse MJ, McCarthy ML, Jones AL, et al. The insensate foot following severe lower extremity trauma: an indication for amputation? J Bone Joint Surg Am. 2005;87:2601–8.
11. Kutz JE, Jupiter JB, Tsai TM. Lower limb replantation: a report of nine cases. Foot Ankle. 1983;3:197–202.
12. Battiston B, Tos P, Pontini I, et al. Lower limb replantations: indications and a new scoring system. Microsurgery. 2002;22:187–92.
13. Hierner R, Betz A, Pohlemann T, et al. Long-term results after lower-leg replantation. Eur J Trauma. 2005;31:389–97.

How to Cite this Article

Leo L, Joseph AX | Revascularization and Reconstruction of a Near Total Amputation of Foot | August-September 2022; 10(2): 44-47.